



HAL
open science

Use of contrast-enhanced ultrasonography for the detection of a feline insulinoma

Mario Cervone, Mathieu Harel, Emilie Ségard-Weisse, Emilie Krafft

► To cite this version:

Mario Cervone, Mathieu Harel, Emilie Ségard-Weisse, Emilie Krafft. Use of contrast-enhanced ultrasonography for the detection of a feline insulinoma. *Journal of Feline Medicine and Surgery Open Reports*, 2019, 5 (2), pp.2055116919876140. 10.1177/2055116919876140 . hal-04845287

HAL Id: hal-04845287

<https://vetagro-sup.hal.science/hal-04845287v1>

Submitted on 19 Dec 2024

HAL is a multi-disciplinary open access archive for the deposit and dissemination of scientific research documents, whether they are published or not. The documents may come from teaching and research institutions in France or abroad, or from public or private research centers.

L'archive ouverte pluridisciplinaire **HAL**, est destinée au dépôt et à la diffusion de documents scientifiques de niveau recherche, publiés ou non, émanant des établissements d'enseignement et de recherche français ou étrangers, des laboratoires publics ou privés.



Distributed under a Creative Commons Attribution - NonCommercial 4.0 International License



Use of contrast-enhanced ultrasonography for the detection of a feline insulinoma

Mario Cervone, Mathieu Harel, Emilie Ségard-Weisse and Emilie Krafft

Journal of Feline Medicine and Surgery Open Reports
1–7

© The Author(s) 2019

Article reuse guidelines:

sagepub.com/journals-permissions

DOI: 10.1177/2055116919876140

journals.sagepub.com/home/jfmsopenreports

This paper was handled and processed by the American Editorial Office (AAFP) for publication in *JFMS Open Reports*



Abstract

Case summary A 14-year-old cat was presented with a 2-week history of ataxia, seizure-like episodes, vomiting and weight loss. Serum biochemistry revealed severe hypoglycaemia, associated with low serum fructosamine and high insulin concentrations. On abdominal ultrasound, a focal hypoechoic well-defined mass in the left limb of the pancreas was identified and the presence of an additional smaller nodule was suspected. Contrast-enhanced ultrasonography (CEUS) confirmed the presence of both lesions and revealed a third, even smaller nodule. Partial pancreatectomy was performed. Histopathology and immunohistochemistry confirmed the presence of a multifocal insulinoma. Six months later, the cat presented with tenesmus and obstipation. A colorectal adenocarcinoma was diagnosed with histopathology after partial excision of a colorectal mass. The cat was euthanased a month later owing to recurrent episodes of severe obstipation.

Relevance and novel information This is the first clinical description of the use of CEUS in the diagnosis of feline insulinoma. Furthermore, the available scientific literature on feline insulinoma was reviewed.

Keywords: Feline insulinoma; contrast-enhanced ultrasonography; CEUS; immunohistochemistry

Accepted: 22 August 2019

Case description

A 14-year-old neutered male domestic shorthair cat was presented with a 2-week history of ataxia, seizure-like episodes, vomiting and weight loss. On clinical examination the patient was lethargic. Body condition score was 5/9. Mucous membranes were pale. On thoracic auscultation, an intermittent gallop rhythm was detected. On neurological examination, the cat appeared to be disoriented and ataxic, with an inconsistent menace response. No other neurological deficits of cranial nerves or spinal reflexes were identified. Ophthalmic examination revealed no abnormalities. Systolic arterial blood pressure was normal.

An automated complete blood count revealed a mild, non-regenerative anaemia (haematocrit 28%; reference interval [RI] 30–47%). Serum biochemical abnormalities included severe hypoglycaemia (0.2 g/l; RI 0.7–1.6 g/l), mildly increased alanine aminotransferase (178 U/l; RI 20–130 U/l) and moderate hypokalaemia (3.1 mmol/l; RI 3.7–5.8 mmol/l).

Mild azotaemia with a blood urea nitrogen of 0.7 g/l (RI 0.2–0.6 g/l) and a creatinine of 18 mg/l (RI 5–16 mg/l) was also noted. Urine specific gravity was measured at 1.015, with no further abnormality on urinalysis. Serum testing for feline leukaemia virus antigen and feline immunodeficiency virus antibodies yielded negative results. Total thyroxine concentration was within the RI (28 nmol/l; RI 20–50 nmol/l). Serum fructosamine concentration was low (160 µmol/l; RI 220–340 µmol/l), while insulin concentration was increased

Université de Lyon, VetAgro Sup, Campus vétérinaire de Lyon, Département des animaux de compagnie de loisir et de sport, Marcy L'Etoile, France

Corresponding author:

Mario Cervone, Université de Lyon, VetAgro Sup, Campus vétérinaire de Lyon, Département des animaux de compagnie de loisir et de sport, 69280, Marcy L'Etoile, France
Email: mariocervone@live.it



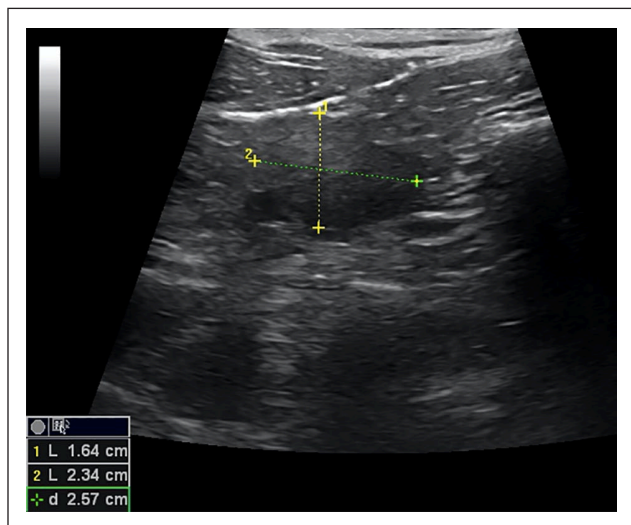


Figure 1 Focal hypoechoic well-defined mass in the left limb of the pancreas, measuring 16 × 23 mm and deforming the pancreatic margins, detected at abdominal ultrasound performed with a linear probe. Cranial is to the left of the image

(47 mU/l; RI 0–25 mU/l). An insulin-secreting malignant (pancreatic or extra-pancreatic) or benign (beta cells hyperplasia) neoplasm was therefore strongly suspected.

Supportive care included intravenous fluid therapy with dextrose and potassium supplementation (saline solution [0.45% NaCl] with 2.5% dextrose and 28mEq/l potassium chloride) and monitoring of blood glucose concentration.

On abdominal ultrasound, a focal hypoechoic well-defined mass in the left limb of the pancreas was identified (Figure 1), and the presence of an additional smaller nodule was suspected. The pancreas was otherwise normal in size and echogenicity, and associated lymph nodes were not measurably enlarged. The liver was normal, but the ultrasonographic appearance of the kidneys was consistent with chronic renal disease. Thoracic radiography, with three views, and complete echocardiography revealed no abnormality. Cytological examination of samples from the pancreatic mass, obtained under sedation via ultrasound-guided fine-needle aspiration, revealed clusters of intact cells with indistinct cytoplasmic borders and uniform round nuclei containing prominent nucleoli (Figure 2). Based on these findings, an insulin-secreting pancreatic neoplasm was suspected.

Prior to surgery, the cat was managed medically with prednisolone (0.5 mg/kg q24h) and fed small, frequent meals. CT was the suggested next step to evaluate metastatic spread and to better define the pancreatic lesions but was declined by the owners for financial reasons. Therefore, tissue contrast-enhanced ultrasonography (CEUS) was performed, although it did not permit the investigation of the thorax for metastasis.

Two CEUS studies were undertaken under general anaesthesia with butorphanol (0.2 mg/kg IV), dexmedetomidine (1 µg/kg IV) and propofol (2 mg/kg IV),

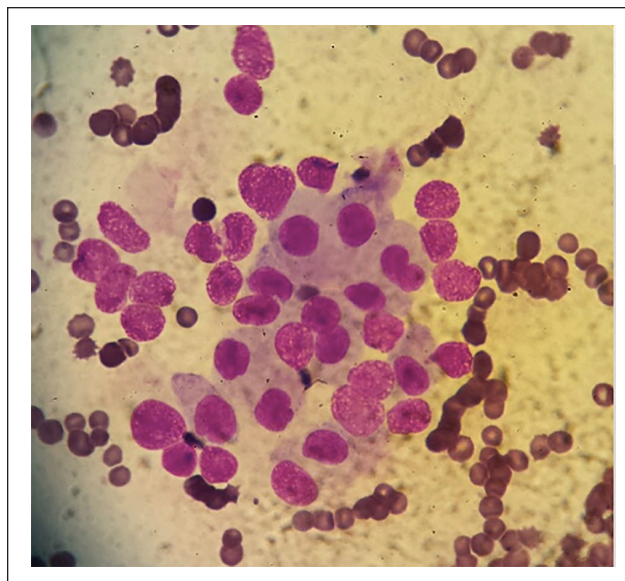


Figure 2 Cytological examination of the pancreatic mass samples, obtained by ultrasound-guided fine-needle aspiration, revealing clusters of intact cells showing indistinct cytoplasmic borders and uniform round nuclei containing a prominent nucleolus (modified Romanowsky stain, × 1000)

each employing 1.0 ml of a reconstituted microbubble contrast agent (Sonovue; Bracco International). Ultrasound was performed using a linear probe (2–8 MHz) on conventional B mode. In the first study, the liver was evaluated in the transverse plane from 10s before, up until 3 min after contrast administration. Homogeneous contrast uptake by the hepatic parenchyma was observed throughout the time following administration.

The second study, performed 30 mins later, aimed to evaluate the pancreatic parenchyma and followed the same time frame as for the first study ultrasound. Uniform enhancement of the pancreas was observed, with a rapid increase in its echogenicity, peaking at 30s post-injection and followed by a rapid wash out. The previously identified hypoechoic mass presented a lower contrast uptake than the surrounding parenchyma at peak contrast enhancement, and therefore appeared by subtraction.

In addition, two ill-defined smaller nodules were also identified by subtraction at 30s post-injection, owing to their relatively poor contrast enhancement, in the left pancreatic limb, both caudally to the larger mass. A prominent blood vessel (Figure 3) was detected in the centre of the most caudal nodule, appearing as a linear, highly contrast-enhanced structure. Of these two additional nodules, one was suspected on conventional B-mode ultrasound, while the other was not seen owing to its isoechoic appearance and the absence of distortion of the pancreatic margins. These features were considered suggestive of multifocal pancreatic disease.

A ventral midline laparotomy was performed, and the pancreas was exposed. The larger nodule was

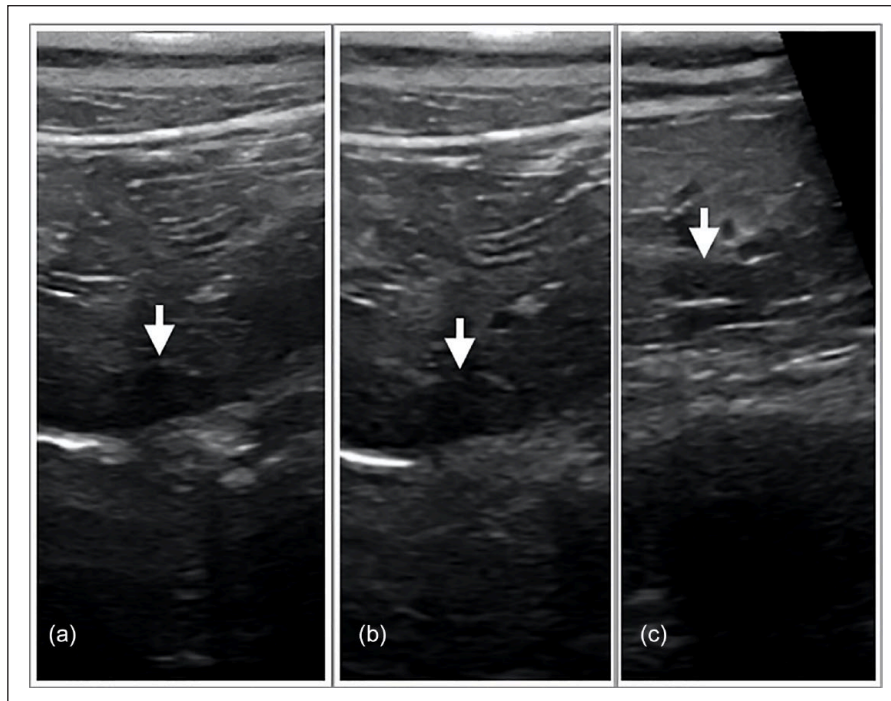


Figure 3 Evaluation of the pancreatic parenchyma with contrast-enhanced ultrasonography. An ill-defined small nodule is identified by subtraction in the left limb of pancreas (arrow), (a) 10 and (b) 30 s after injection of Sonovue contrast agent. (c) A prominent marginal feeding vessel is detected 45 s after in the centre of the nodule, appearing as a linear highly contrast-enhancing structure

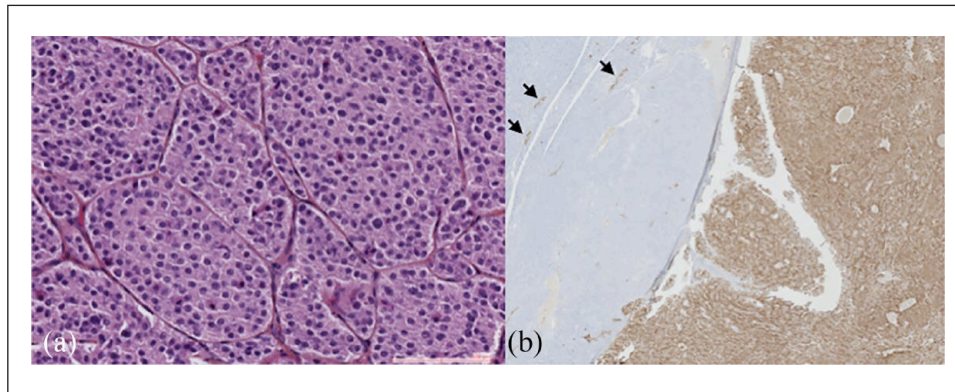


Figure 4 Histopathological evaluation of the pancreatic parenchyma harbouring the larger nodule. (a) Islet cell tumour (carcinoma) composed of round uniform cells with round uniform nuclei (haematoxylin and eosin staining, $\times 1000$). (b) Immunohistochemical staining with human antibody against insulin, showing normal pancreatic parenchyma with the presence of Langerhans islets (positive control; arrows) and a strong and homogeneous insulin staining of neoplastic cells in the right side of the image ($\times 400$)

macroscopically visible, while the smaller ones were identified by gentle palpation of the pancreas. After visualisation of the cranial and caudal pancreaticoduodenal artery, hemi-pancreatectomy of the left lobe of the pancreas was performed by suture fracture technique.

A multifocal islet cell carcinoma was diagnosed at histopathology (Figure 4a). At immunohistochemistry, neoplastic cells showed marked positive staining for insulin (Figure 4b), and negative staining for chromogranin A,

glucagon and somatostatin. Blood glucose concentration remained high (varying from 1.8–4 g/l) during the first few days postoperatively, but subsequently normalised (1.5 g/l at discharge 5 days later). Prednisolone treatment was progressively tapered off over 10 days after surgery. The cat was thereafter clinically normal, and the owner declined further monitoring for tumour recurrence.

Six months later, the cat was presented with faecal tenesmus, severe obstipation and vomiting. No abnormalities were recorded at urinalysis, haematology and

serum biochemistry. On abdominal radiography, severe colonic dilatation with partially mineralised faeces were observed. Because of severe obstipation, the colon was not easily investigable at abdominal ultrasound. As further non-invasive testing was declined (repeating abdominal ultrasound after enema and/or abdominal and pelvis CT), an exploratory laparotomy was performed. A large luminal mass infiltrating the colorectal junction wall was identified and resected. Histopathology was consistent with an adenocarcinoma with infiltrated margins. The cat was euthanased a month later due to recurrent episodes of severe obstipation.

Discussion

Pancreatic endocrine neoplasms are rare in domestic animals and include insulinoma, glucagonoma, gastrinoma, pancreatic polypeptide-secreting islet tumour and somatostatinoma.^{1,2} Benign inflammatory pancreatic hyperplasia has also been described in a cat.³ Insulinomas are uncommon tumours of dogs,^{4,5} and only eight cases have been reported in feline medicine (Table 1). In cats, evidence to date indicates an increased incidence in older patients (Table 1), as in the case discussed here. There is no reported sex predilection in dogs nor in cats.^{4,5} Two of the eight reported feline cases were Siamese (Table 1).

Suspicion of insulinoma depends on suggestive clinical signs, as well as persistent hypoglycaemia at serum biochemistry.^{4,13,14} In cats, the most common clinical signs include weakness, lethargy and seizure-like episodes (Table 1). Hypoglycaemia can vary with normoglycaemic episodes, related to the action of counter-regulatory hormones that antagonise the effects of insulin, creating a compensatory increase in blood glucose concentration.⁶ Thus, patients occasionally can be normoglycaemic at presentation, complicating the diagnosis. Differential diagnoses for hypoglycaemia in adult cats include insulin-secreting neoplasms, hepatic disease, sepsis, hypo-adrenocorticism, storage diseases and, more rarely, beta-cell hyperplasia.³ Insulin-secreting tumours are most frequently suspected by finding hypoglycaemia with concomitant normal-to-increased serum insulin concentration.^{6,15} In our patient, ataxia and seizure-like episodes were reported by the owner and severe hypoglycaemia with concomitant hyperinsulinaemia were detected at admission.

Insulinomas are typically malignant and surgical removal of the pancreatic neoplasm is the recommended treatment in patients with a suspected insulinoma.¹⁶ In 1999, Tobin et al¹⁶ reported a significantly prolonged survival time after surgical removal of canine insulinoma, when compared with medical management alone. Insulinoma can present either as solitary or multifocal lesions,^{17,18} and the prevalence of metastasis is high at the time of diagnosis.^{19,20} Therefore, accurate preoperative

diagnosis, localisation and staging are required to select appropriate candidates for surgery.^{18,19} Conventional ultrasonography (US) and CT are rather effective in detecting insulinomas, but false-negative lymph node metastases and false-positive lesions have been reported with these techniques.²¹ The sensitivity of conventional US in detecting canine insulinoma has been reported to range from 28–75%,^{18,22} and remains operator-dependent.¹⁸ Moreover, in feline medicine, only a single case report describes the use of conventional US to diagnose insulinoma prior to a laparotomic approach.¹² Nuclear scintigraphy with radiolabelled somatostatin analogues has been described in the diagnosis, preoperative planning and prognostic assessment of a canine insulinoma, but the cost and availability of this diagnostic modality limits its use.²³

Abdominal US was useful in detecting a pancreatic mass in this case and suggested the presence of an additional smaller pancreatic nodule. The use of another imaging modality was therefore indicated to confirm the presence of multifocal lesions. As CT was declined by the owner, CEUS was considered as an alternative. It is a technique based on intravenous injection of microbubble contrast agents to assess organ perfusion.²⁴ Microbubble contrast agents exist in two forms: blood pool agents and parenchymal agents. In the case described herein, a blood pool agent was used.²⁴ The use of CEUS in the diagnosis of insulinomas was recently evaluated in dogs.^{25,26} Results from both studies showed that there are different enhancement patterns between exocrine (adenocarcinoma) and endocrine (insulinoma) pancreatic tumours in dogs,²⁶ and that the pattern of insulinomas is variable, either hypo- or hyperechoic relative to the surrounding parenchyma. Furthermore, in another study evaluating focal liver lesions in dogs, CEUS had good sensitivity (100%) and specificity (89%) in detecting malignancies.²⁷

In the case described here, CEUS using a second-generation contrast agent (Sonovue) confirmed the presence of additional nodules, one of which was not detected using conventional ultrasonography. Hypoperfusion of these nodules compared to the surrounding pancreatic parenchyma was the key feature leading to their detection. One nodule also presented an aberrant blood vessel. This pattern of contrast uptake is similar to previously reported findings in a dog.²⁵ However, in the present study, CEUS was performed using conventional B-mode without harmonic optimised software to detect intravenous contrast media. The contrast enhancement pattern may have been different using this particular technique.

CEUS has also been described as useful in the diagnosis of liver metastases in a cat with hemangiosarcoma.²⁸ However, a parenchymal agent was used in that study, which is characterised by a vascular and a parenchymal

Table 1 Summary of published feline insulinoma cases

Signalment	Initial presentation	Clinical findings	Bloodwork abnormalities	Anatomic localisation	Treatment	Histology and immunohistochemistry	Survival time	Reference
14-year-old MN DSH cat	Seizure-like episodes	NA	Mild thrombocytopenia, hypoglycaemia, normal insulinaemia and mild azotaemia	Left limb of the pancreas	Surgery	Carcinoma No immunohistochemistry	32 months	Greene and Bright ⁴
14-year-old FN DSH cat	Weakness, lethargy, decreased appetite, diarrhoea, weight loss, seizures	Hypothermia, bradycardia, gallop rhythm sound, inconsistent menace response	Hypoglycaemia and mild azotaemia	Left limb of the pancreas	Surgery	Carcinoma Chromogranin A+	1 month	Kraje ⁶
14-year-old male Siamese cat	Episodic staggering and leg and facial twitching	NA	Hypoglycaemia, increased insulinaemia	Left limb of the pancreas	Surgery	Carcinoma Insulin+, somatostatin+, islet amyloid polypeptide+	7 months	O'Brien et al ⁷
16-year-old MN Japanese domestic cat	Seizures and dystasia	No abnormalities	Hypoglycaemia	Right lobe of the pancreas	Surgery	Carcinoma Insulin+, chromogranin A+, somatostatin+, glucagon-, amyloid+	NA	Kanaya et al ⁸
17-year-old male Siamese cat	Seizures	Weakness, hypothermia	Regenerative anaemia Hypoglycaemia and increased insulinaemia	Angle of the pancreas	Surgery	Carcinoma Insulin+, chromogranin A+, somatostatin+, glucagon+, neuron-specific enolase+	18 months	Hawks et al ⁹
13-year-old MN DLH cat	Lethargy, exercise intolerance, neck ventroflexion, constipation	Systolic murmur, neck mass	Thrombocytosis Hypoglycaemia, hypokalaemia, total and ionised hypercalcaemia, normal PTH and normal PTH-rp, increased aldosteronaemia	Right lobe of the pancreas	Surgery	Undifferentiated neuroendocrine neoplasm of islet cell origin Insulin+, chromogranin A and B+, somatostatin-, glucagon+, protein gene product 9.5+, synaptophysin+, gastrin-	NA	Brent Reimer et al ¹⁰
Geriatric DSH cat	NA	NA	Hypoglycaemia, increased insulinaemia	NA	NA	Islet cell tumour Insulin+, chromogranin A+, somatostatin+, glucagon-, pancreatic polypeptide-	NA	Jackson et al ¹¹
15-year-old FN DSH cat	Paroxysmal falling over and trembling	Mild generalised muscle tremors	Hypoglycaemia, Slightly increased T4 level	Left pancreatic lobe	Surgery	Islet cell adenoma Insulin+	32 months	Schaub and Wigger ¹²

MN = male neutered; DSH = domestic shorthair; NA = data not reported; FN = female neutered; DLH = domestic longhair; PTH = parathyroid hormone; PTH-rp = parathyroid hormone-related peptide; T4 = thyroxine; + = positive immunohistochemical staining; - = negative immunohistochemical staining

phase, unlike blood pool contrast agents. Furthermore, as there was no evidence, in this case, of metastasis either before or after surgery at the 6-month follow-up, the use of CEUS to detect metastases in feline insulinoma was not evaluated.

Further studies are warranted to evaluate the use of CEUS in the diagnosis and abdominal staging of insulinoma in both dogs and cats, using different microbubble contrast agents. Nevertheless, in the case described herein, the use of CEUS with conventional B-mode allowed accurate detection of all pancreatic nodules, with no other lesion found on gross and histopathological examination and no further hypoglycaemic episode observed in the patient postoperatively.

In the present case, the diagnosis of islet cell carcinoma was confirmed on routine histopathology, while additional immunohistochemistry confirmed its secretory nature. Neoplastic cells stained strongly for insulin, but were negative for chromogranin A, glucagon and somatostatin. Insulin appears always to be expressed in feline insulinomas (Table 1), but the staining pattern is reported to be variable, appearing as patchy or diffuse.¹¹ Glucagon and somatostatin immunoreactivity was not detected in this case, possibly reflecting variable expression of these hormones, as previously reported (Table 1). The lack of chromogranin A expression was unexpected as this endocrine marker seems to be a consistent feature of feline insulinomas (Table 1). However, chromogranin A-negative insulinomas have been described in dogs,²⁹ and canine insulinomas are more extensively described in the scientific literature. It is also possible that a lack of cross-reactivity with the human antibody used in this case generated a false-negative result.

A review of all reported cases of feline insulinoma has suggested that the prognosis is good for cats following surgical removal (Table 1). Accordingly, in this case, complete remission of clinical signs and biochemical abnormalities was achieved for several months following partial pancreatectomy. Unfortunately, the development of a colorectal adenocarcinoma, with associated obstructive obstipation, led to the owner's decision to euthanase the animal 6 months later. As no immunohistochemistry was performed on the resected colorectal tumour, it was not possible to determine if the lesion stained for insulin. However, the absence of concurrent hypoglycaemia supports the hypothesis that this lesion was not insulin-secreting and represented a distinct primary tumour rather than a metastasis of the insulinoma.

Conclusions

We describe here a case of feline pancreatic insulinoma in which CEUS allowed the identification of an additional pancreatic nodule, not detected on conventional

ultrasonographic examination. Further studies are warranted to investigate the use of this technique in the evaluation of pancreatic lesions in cats.

Acknowledgements The authors would like to thank Dr Flora Poizat (Institut Paoli-Calmette Marseille, France) for performing immunohistochemistry, and Madeline Mestas for her help with the language revision.

Conflict of interest The authors declared no potential conflicts of interest with respect to the research, authorship, and/or publication of this article.

Funding The authors received no financial support for the research, authorship, and/or publication of this article.

Ethical approval This work involved the use of non-experimental animal(s) only (owned or unowned), and followed established internationally recognised high standards ('best practice') of individual veterinary clinical patient care. Ethical approval from a committee was not necessarily required.

Informed consent Informed consent (either verbal or written) was obtained from the owner or legal custodian of all animal(s) described in this work for the procedure(s) undertaken. No animals or humans are identifiable within this publication, and therefore additional informed consent for publication was not required.

References

- Jubb KVF and Stent AW. **Pancreas**. In: Maxie I and Grant M (eds). Pathology of domestic animals. St Louis, MO: Elsevier, 2007, pp 353–375.
- Morrison J and Dobson J. **Endocrine system**. In: Morrison J and Dobson J (eds). Small animal oncology. Oxford: Wiley-Blackwell, 2001, pp 221–227.
- Hambrook LE, Ciavarella AA, Nimmo SJ, et al. **Hyperinsulinaemic, hypoglycaemic syndrome due to acquired nesidioblastosis in a cat**. *JFMS Open Rep* 2016; 2: DOI: 10.1177/2055116916657846.
- Greene SN and Bright RM. **Insulinoma in a cat**. *J Small Anim Pract* 2008; 49: 38–40.
- Elie MS and Zerbe CA. **Insulinoma in dogs, cats, and ferrets**. *Comp Cont Educ Pract* 1995; 17: 51–59.
- Kraje AC. **Hypoglycaemia and irreversible neurologic complications in a cat with insulinoma**. *J Am Vet Med Assoc* 2003; 6: 812–814.
- O'Brien TD, Norton F, Turner TM, et al. **Pancreatic endocrine tumour in a cat: clinical, pathological, and immunohistochemical evaluation**. *J Am Anim Hosp Assoc* 1990; 26: 453–457.
- Kanaya S, Goryo M, Sasaki G, et al. **Islet cell tumour in a cat** [article in Japanese]. *J Jpn Vet Med Assoc* 2009; 62: 810–814.
- Hawks D, Peterson ME, Hawkins KL, et al. **Insulin-secreting pancreatic (islet cell) carcinoma in a cat**. *J Am Vet Med Assoc* 1992; 6: 193–196.

- 10 Brent Reimer S, Pelosi A, Frank JD, et al. **Multiple endocrine neoplasia type I in a cat.** *J Am Vet Med Assoc* 2005; 1: 101–104.
- 11 Jackson TC, Debey B, Lindbloom-Hawley S, et al. **Cellular and molecular characterization of a feline insulinoma.** *J Vet Intern Med* 2009; 23: 383–387.
- 12 Schaub S and Wigger A. **Ultrasound-aided diagnosis of an insulinoma in a cat.** *Tierarztl Prax Ausg K Kleintiere Heimtiere* 2013; 41: 338–342.
- 13 Caplan ER, Peterson ME, Mullen HS, et al. **Diagnosis and treatment of insulin-secreting pancreatic islet cell tumours in ferrets: 57 cases (1986–1994).** *J Am Vet Med Assoc* 1996; 209: 1741–1745.
- 14 Weiss CA, Williams BH and Scott MV. **Insulinoma in the ferret: clinical findings and treatment, comparison of 66 cases.** *J Am Vet Med Assoc* 1998; 34: 471–475.
- 15 Gough A. **Laboratory findings.** In: Gough A (ed). *Differential diagnosis in small animal medicine.* Oxford: Blackwell Publishing, 2007, p 307.
- 16 Tobin RL, Nelson RW, Lucroy MD, et al. **Outcome of surgical versus medical treatment of dogs with beta cell neoplasia: 39 cases (1990–1997).** *J Am Vet Med Assoc* 1999; 215: 226–230.
- 17 Feldman EC and Nelson RW. **Beta-cell neoplasia: insulinoma.** In: Feldman EC and Nelson RW (eds). *Canine and feline endocrinology and reproduction.* 3rd ed. St Louis, MO: Elsevier, 2004, pp 616–644.
- 18 Goutal CM, Brugmann BL, Ryan KA, et al. **Insulinoma in dogs: a review.** *J Am Anim Hosp Assoc* 2012; 48: 151–163.
- 19 Leifer CE, Peterson ME and Matus RE. **Insulin-secreting tumour: diagnosis and medical and surgical treatment in 55 dogs.** *J Am Vet Med Assoc* 1986; 188: 60–64.
- 20 Trifonidou MA, Kirpenstiin J and Robben JH. **A retrospective evaluation of 51 dogs with insulinoma.** *Vet Q* 1998; 20: 114–115.
- 21 Robben JH, Pollak YWEA, Kirpensteijn J, et al. **Comparison of ultrasonography, computed tomography, and single-photon emission computed tomography for the detection and localization of canine insulinoma.** *J Vet Intern Med* 2005; 19: 5–22.
- 22 Lamb CR, Simpson KW, Boswood A, et al. **Ultrasonography of pancreatic neoplasia in the dog: a retrospective review of 16 cases.** *Vet Rec* 1995; 137: 65–68.
- 23 Lester NV, Newell SM, Hill RC, et al. **Scintigraphic diagnosis of insulinoma in a dog.** *Vet Radiol Ultrasound* 1999; 40: 174–178.
- 24 Marolf AJ. **Diagnostic imaging of the hepatobiliary system: an update.** *Vet Clin North Am Small Anim Pract* 2017; 47: 555–568.
- 25 Nakamura K, Lim SY, Ochiai K, et al. **Contrast-enhanced ultrasonographic findings in three dogs with pancreatic insulinoma.** *Vet Radiol Ultrasound* 2015; 56: 55–62.
- 26 Vanderperren K, Haers H, Van der Vekens E, et al. **Description of the use of contrast-enhanced ultrasonography in four dogs with pancreatic tumours.** *J Small Anim Pract* 2014; 55: 164–169.
- 27 Kanemoto H, Ohno K, Nakashima K, et al. **Characterization of canine focal liver lesions with contrast-enhanced ultrasound using a novel contrast agent sonazoid.** *Vet Radiol Ultrasound* 2009; 50: 188–194.
- 28 Webster N and Holloway A. **Use of contrast ultrasonography in the diagnosis of metastatic feline visceral haemangiosarcoma.** *J Feline Med Surg* 2008; 10: 388–394.
- 29 Myers NC, Andrews GA and Chard-Bergstrom C. **Chromogranin A plasma concentration and expression in pancreatic islet cell tumours of dogs and cats.** *Am J Vet Res* 1997; 58: 615–620.