



HAL
open science

Infection with SARS-CoV-2 variant B.1.1.7 detected in a group of dogs and cats with suspected myocarditis

Luca Ferasin, Matthieu Fritz, Heidi Ferasin, Pierre Becquart, Sandrine Corbet, Meriadeg Ar Gouilh, Vincent Legros, Eric Leroy

► **To cite this version:**

Luca Ferasin, Matthieu Fritz, Heidi Ferasin, Pierre Becquart, Sandrine Corbet, et al.. Infection with SARS-CoV-2 variant B.1.1.7 detected in a group of dogs and cats with suspected myocarditis. *Veterinary Record*, 2021, 189 (9), 10.1002/vetr.944 . hal-04567221

HAL Id: hal-04567221

<https://vetagro-sup.hal.science/hal-04567221v1>


Submitted on 7 Oct 2024

HAL is a multi-disciplinary open access archive for the deposit and dissemination of scientific research documents, whether they are published or not. The documents may come from teaching and research institutions in France or abroad, or from public or private research centers.

L'archive ouverte pluridisciplinaire **HAL**, est destinée au dépôt et à la diffusion de documents scientifiques de niveau recherche, publiés ou non, émanant des établissements d'enseignement et de recherche français ou étrangers, des laboratoires publics ou privés.

ORIGINAL RESEARCH

Infection with SARS-CoV-2 variant B.1.1.7 detected in a group of dogs and cats with suspected myocarditis

Luca Ferasin^{1,2}  | Matthieu Fritz³ | Heidi Ferasin^{1,2} | Pierre Becquart³ | Sandrine Corbet⁴ | Meriadeg Ar Gouilh^{3,4,5} | Vincent Legros^{6,7} | Eric M. Leroy³

¹ The Ralph Veterinary Referral Centre, Marlow, Buckinghamshire, UK

² Specialist Veterinary Cardiology Consultancy, Four Marks, Hampshire, UK

³ Institut de Recherche pour le Développement (IRD), Maladies Infectieuses et vecteurs: Ecologie, génétique, Evolution et Contrôle (MIVEGEC) (Université de Montpellier, IRD, CNRS), Montpellier, France

⁴ Laboratoire de Virologie, Centre Hospitalo-Universitaire, Caen, France

⁵ Groupe de Recherche sur l'Adaptation Microbienne (GRAM 2.0), Normandie Univ, UNICAEN, Caen, France

⁶ CIRI - Centre International de Recherche en Infectiologie, Team EVIR, Univ Lyon, Université Claude Bernard Lyon 1, Lyon, France

⁷ Université de Lyon, VetAgro Sup, Marcy-l'Etoile, France

Correspondence

Luca Ferasin, The Ralph Veterinary Referral Centre, Marlow, Buckinghamshire SL7 1YG, UK.

Email: luca@cardiospecialist.co.uk

Eric M. Leroy, UMR IRD-CNRS-UM, 911 Ave Agropolis, 34394 Montpellier, France.

Email: eric.leroy@ird.fr

Luca Ferasin, Matthieu Fritz, Heidi Ferasin, and Pierre Becquart contributed equally to this work.

Funding information

French National Agency for Research and IDEXLYON project of Université de Lyon as part of the 'Programme Investissements d'Avenir, Grant/Award Numbers: ANR-RA-COVID-19, ANR-16-IDEX-0005

Abstract

Background: Domestic pets can contract severe acute respiratory syndrome coronavirus 2 (SARS-CoV-2) infection; however, it is unknown whether the UK B.1.1.7 variant can more easily infect certain animal species or increase the possibility of human-to-animal transmission.

Methods: This is a descriptive case series reporting SARS-CoV-2 B.1.1.7 variant infections in a group of dogs and cats with suspected myocarditis.

Results: The study describes the infection of domestic cats and dogs by the B.1.1.7 variant. Two cats and one dog were positive to SARS-CoV-2 PCR on rectal swab, and two cats and one dog were found to have SARS-CoV-2 antibodies 2–6 weeks after they developed signs of cardiac disease. Many owners of these pets had developed respiratory symptoms 3–6 weeks before their pets became ill and had also tested positive for COVID-19. Interestingly, all these pets were referred for acute onset of cardiac disease, including severe myocardial disorders of suspected inflammatory origin but without primary respiratory signs.

Conclusions: These findings demonstrate, for the first time, the ability for pets to be infected by the B.1.1.7 variant and question its possible pathogenicity in these animals.

INTRODUCTION

The COVID-19 pandemic secondary to severe acute respiratory syndrome coronavirus 2 (SARS-CoV-2) variant, carrying the spike (S) protein amino acid change D614G (referred to as B.1 variant), has encompassed several millions of cases around the world. This global situation has favoured the appearance of numerous genomic mutations, some of which have generated variants having selective

advantages.¹ Three notable variants emerged in late autumn 2020 in several countries, which then spread rapidly across the world, including B.1.1.7 (also referred to as 20I/N501Y.V1) first detected in England, B.1.351 (20J/N501Y.V2) first detected in South Africa and the more recently identified “Brazil” variant P.1 (20I/N501Y.V3).² These three variants carry a constellation of genetic mutations, including those at the level of the S protein receptor-binding domain (RBD), which is essential for binding

to the cell host ACE-2 receptor to facilitate virus entry.

The B.1.1.7 variant, also referred to as variant of concern (VOC) 202012/01 or 20I/501Y.V1, is estimated to have emerged in September 2020 in Kent, a county in the south east of England, and rapidly outcompeted pre-existing variants in England as the consequence of an increased transmissibility and infectivity.² Multiple lines of evidence indicate that its enhanced transmissibility is driven by the N501Y mutation and the amino acid $\Delta 69/70$ deletion in RDB.³ Consequently, the incidence of B.1.1.7 increased rapidly during a national lockdown implemented by the Government of the United Kingdom from 5 November to 2 December 2020, despite rigorous restrictions, causing an extraordinary surge of COVID-19 cases particularly affecting the Greater London area. As of 7 February 2021, VOC 202012/01 comprised roughly 95% of new SARS-CoV-2 infections in the United Kingdom and has now been identified in at least 86 countries.

The most dominant clinical manifestations of COVID-19 are characterised by acute respiratory signs associated with high mortality. However, with rapidly evolving research on COVID-19 in people, cardiovascular manifestations were also found to occur in 20%–30% of hospitalised patients, including signs of myocarditis, which have been reported in multiple case reports and review articles.⁴

Several cases of SARS-CoV-2 infection have also been reported worldwide in domestic pets (especially cats and dogs) and it has been suggested that these animals became infected by their owners or handlers. Infections of domestic pets mostly resulted in unapparent to mild digestive and respiratory symptoms such as cough, runny nose, sneezing and conjunctivitis.^{5–8}

Intriguingly, despite the uncontrolled surge of COVID-19 cases occurring in the United Kingdom since November 2020, natural infection of any animal by the UK B.1.1.7 variant has not been documented, neither in England nor anywhere else. However, in this observational study, we report the first cases of domestic cats and dogs infected by the UK variant of SARS-CoV-2, as well as a potential association with cardiovascular disease, which was the initial main health concern and reason for a referral to a cardiology service.

A total of 26 canine and feline patients were diagnosed with suspected myocarditis at The Ralph Veterinary Referral Centre (TRVRC), based on the outskirts of London (UK), between December 2020 and March 2021. Notably, many owners and handlers of these pets with myocarditis had developed COVID-19 respiratory symptoms and tested PCR positive for COVID-19 within 3–6 weeks before their pets became ill. Interestingly, two pet carers also reported to have developed COVID-associated severe myocarditis a few weeks before the onset of clinical signs in their pets. Given this coincidence, coupled with the intriguing simultaneous presence of suspected myocarditis in these pets and the B.1.1.7 COVID-19 outbreak in the

United Kingdom, we decided to investigate SARS-CoV-2 infection in these animals.

MATERIALS AND METHODS

Diagnosis of myocarditis

The clinical suspicion of myocarditis of cats and dogs referred to TRVRC was based on the absence of any previous history of heart disease, the per-acute onset of clinical signs characterised by lethargy, inappetence, syncopal events, tachypnoea/dyspnoea secondary to the presence of congestive heart failure (often confirmed on thoracic radiographs), the presence of significant ventricular arrhythmias on electrocardiographic (ECG) recording, the substantial elevation of cardiac troponin-I, as well as the evidence of myocardial disease on echocardiography (Table 1).⁹ Although a definitive diagnosis of myocarditis would require endomyocardial biopsy (EMB), which can also allow an aetiological diagnosis in many cases, this method was not considered due to the critical presentation of our patients. Additional diagnostic investigations were performed, whenever possible, in the attempt to rule out the most common causes of myocarditis in dogs and cats, and included enzyme-linked immunosorbent assay (ELISA) for the simultaneous detection of feline leukaemia virus (FeLV) antigen and antibodies to feline immunodeficiency virus (FIV) (cats only), serology for *Toxoplasma* (IgG and IgM antibodies), *Anaplasma* and Lyme disease, as well as PCR testing for *Babesia*, *Anaplasma* and *Ehrlichia*.

Case selection and sampling

Serum samples as well as oro-nasopharyngeal and rectal swabs were collected from seven animals (six cats and one dog) at initial presentation at TRVRC between 22 January and 10 February 2021 (Table 1). During the same period, blood samples were collected from four other pets (two cats and two dogs) during their recovery phase, 2–6 weeks after they developed signs of suspected myocarditis. Written owner consent was obtained in all cases before collecting any samples for diagnostic investigations.

Following collection, all samples were stored at -20°C until transportation in ice to MIVEGEC laboratory at Montpellier, France for serological and virological investigations. Oro-nasopharyngeal and rectal swabs were tested using the droplet digital RT-PCR (ddPCR) targeting one region specific to the SARS-CoV-2 N gene and two regions of the spike protein gene specific to the three current predominant SARS-CoV-2 variants, namely 20I/N501Y.V1, 20J/N501Y.V2 and 20I/N501Y.V3. One target region, containing the N501Y mutation, is common to the three variants and the other target region, containing the $\Delta 69-70$ deletion, is specific to the B.1.1.7 variant. Sera were tested for SARS-CoV-2-specific IgG using three microspheres

TABLE 1 Characteristics of dogs and cats diagnosed with myocarditis at The Ralph Veterinary Referral Centre between 22 January and 10 February 2021

Species	Breed	Age	Sex	Days	General symptoms	T, °C	Cardiac abnormalities	Troponin (ng/ml)	COVID-19+ contact	SerologyN protein	Serology RBD	SerologyS trimeric	SN	SARS-CoV-2PCR (rectal)	SARS-CoV-2PCR (nasoph)
BBK	Cat	9	M	2	Lethargy, inappetence	37.1	CHF	7.9	Yes	-	-	-	-	-	-
HY	Cat	9	M	2	Lethargy, inappetence	37.0	CHF, VA	0.68	Yes	-	-	-	-	33 copies RNA/ μ l	-
CH	Cat	12	F	2	Lethargy	35.2	CHF, VA	6.8	Unknown	-	-	-	-	-	-
LL	Cat	10	F	3	Syncope	37.9	CHF, VA	45.6	Unknown	-	-	-	-	12 copies RNA/ μ l	-
MR	Dog	9	F	4	Lethargy, inappetence, haemorrhagic diarrhoea	37.6	VA	43.5	Yes	-	-	-	-	13 copies RNA/ μ l	-
DB	Cat	9	M	8	Lethargy	37.8	CHF	1.31	Unknown	+	-	-	-	-	-
FB	Cat	1	M	10	Lethargy, inappetence	37.3	CHF	12.1	Unknown	-	-	-	-	-	-
DP	Dog	8	F	14	Syncope	38.0	CHF, VA	2.5	Unknown	-	-	-	-	NA	NA
SC	Cat	1	F	28	Lethargy	38.5	CHF	4.92	Yes	+	+	+	-	NA	NA
KFO	Dog	8	M	37	Syncope	38.2	VA	61.1	Yes	-	+	+	+	NA	NA
OR	Cat	1	M	64	Lethargy	37.5	CHF, VA	0.83	Unknown	-	-	-	-	NA	NA

Abbreviations: CHF, congestive heart failure; Days, days between onset of clinical signs and sample collection for COVID-19; DSH, domestic shorthair cat; NA, not available; T, rectal temperature; VA, ventricular arrhythmia.

immunoassays (MIA) detecting IgG binding to the N protein, the S1-RBD-protein or the S trimeric protein, as well as a retrovirus-based pseudoparticle assay detecting SARS-CoV-2-neutralising antibodies.

Laboratory methods

RNA extraction

Rectal and oro/naso-pharyngeal swabs were resuspended by vortexing in 300 μl of PBS. Total RNA was extracted from 200 μl of supernatant of rectal swab and from 200 μl of viral transport medium of nasopharyngeal swabs. Extraction was performed on the extraction system IndiMag 48 (Indical Bioscience), using magnetic bead technology, with the IndiMag Pathogen Kit according to the manufacturer's instructions. The elution volume was 100 μl .

One-step dRT-PCR

The RT-dPCR procedure was performed following the manufacturer's instructions using the QIAcuity 8, 5-plex (Qiagen, Germany), the QIAcuity One-Step Viral RT-PCR Kit (Cat No. 1123145, Qiagen, Germany) and the 24-well 26K Nanoplates (Cat No. 250001, Qiagen, Germany). The ddRT-PCR technique showed higher sensitivity and specificity compared to RT-qPCR for diagnosis of COVID-19.¹⁰ Briefly, the RT-dPCR reaction mixture was assembled as follows: 4 \times One-Step Viral RT-PCR Master Mix 10 μl , 100 \times Multiplex Reverse Transcription Mix 0.4 μl , 20 \times of set of primers and probes 0149, 0130, 0150 (ref IAGE) 2 μl \times 3 (6 μl), RNase-free water 22.6 μl and RNA template 1 μl , in a final volume of 40 μl . 0130 target 2019-nCoV_N2 region NC_045512v2 fluorophore HEX, amplicon length 67 bp. 0149 target S region: mutation deletion 69-70, lineage B1.1 and B1.258, fluorophore HEX, amplicon length 100 bp. 0150 target S region: mutation N501Y, lineage B.1.1.7, fluorophore Cy5, amplicon length 133 bp. The primer used for the N gene-specific detection was the same as described by the CDC for research use only by the Division of Viral Diseases, National Center for Immunization and Respiratory Diseases, Centers for Disease Control and Prevention, Atlanta, GA, USA. For information: 2019-nCoV_N2-F: TTA CAA ACA TTG GCC GCA AA; 2019-nCoV_N2-R: GCG CGA CAT TCC GAA GAA and 2019-nCoV_N2-P: HEX-ACA ATT TGC CCC CAG CGC TTC AG-BHQ1. Both primers and probe for S region detection have been generated using sequence of the UK variant: 20I/501Y.V1 (B.1.1.7 now called as Alpha). As the test for variant detection is under patent by the company (IAGE) that assisted us for the dPCR assay, the sequences for these primers are not publicly available and are filed under the number patent EP20306715.2.

The mixture was prepared in a preplate and then transferred into the 24-well 26K Nanoplate. The latter

was then loaded to the QIAcuity 8 instrument, which is a fully automated system. The workflow included (i) priming and rolling step in order to generate and isolate the chamber partitions; (ii) the amplification step under the following cycling protocol: 50°C for 40 min for reverse transcription, 95°C for 2 min for enzyme activation, 95°C for 5 s for denaturation and 60°C for 30 s for annealing/extension for 40 cycles; and (iii) the imaging step was done by reading in the following channels: FAM, HEX and CY5. The full workflow time was around 2 h for the three steps. The experiments were performed using a negative control (no template control, NTC) and a positive control (a patient's sample confirmed positive by RT-PCR with our routine diagnostic testing). All reactions had at least 25,400 partitions. Data were analysed using the QIAcuity Suite Software V1.1.3 (Qiagen, Germany) and expressed as copies per microlitre.

ONT library preparation and MinION sequencing

Libraries were prepared from droplet PCR products following the Oxford Nanopore Technology (ONT) protocol for native barcoding of genomic DNA sequencing involving the Barcode Ligation Sequencing Kit SQK-LSK108 and the EXP-NBD104/114 Native Barcoding kit. Sequencing libraries were constructed and sequencing was performed according to manufacturer's instructions, as briefly described below. Amplicons were pooled, and bead purified (AMPure XP beads) before end repair with NebNext Ultra II end repair (E7546S, NEB, USA) and subsequent library preparation. End-prepared amplicons were ligated with native barcode adapters NBD04 using Blunt/TA Ligase Master Mix (M0367S, NEB, USA) and then purified with AMPure XP beads. The two samples were then pooled to produce a 60 μl equimass pool used for adapter ligation with 10 μl of the 'Adapter Mix II (AMII)', 20 μl of the NEBnext Quick Ligation reaction and 10 μl of Quick T4 DNA ligase. After 15-min room temperature incubation, the material was bead purified using provided SFB and EB before the final library was mixed and loaded onto an R9.4 flowcell (FLO-MIN106, Oxford Nanopore Technologies, UK), and the run was performed on a MinION Mk1B device (ONT) for 1.5 h.

Genome assembly

Sequencing data were basecalled and subsequently demultiplexed using Guppy GPU basecaller and barcode (Oxford Nanopore Technologies). Reads were then mapped against a custom reference of SARS-CoV-2 genome comprising four Chinese and 70 early French sequences using Bowtie2 (Langmead and Salzberg 2012) and minimap2.¹¹ Finally, consensus sequences based on mapped reads were generated with bcftools consensus (Li 2011). SARS-CoV-2

sequences were deposited on GISAID (registration number GenBank MZ484377-MZ484378).

Microsphere immunoassay

Cat and dog serum samples were tested using a multiplex microsphere immunoassay (MIA). Ten micrograms of three recombinant SARS-CoV-2 antigens, nucleoprotein (N), receptor binding domain (RBD) and trimeric spike (tri-S), were used to capture specific serum antibodies. Distinct MagPlex microsphere sets (Luminex Corp) were respectively coupled to viral antigens using the amine coupling kit (Bio-Rad Laboratories) according to manufacturers' instructions, whereas a microsphere set coupled with recombinant human protein (O6-methylguanine DNA methyltransferase) was used as control in the assay. The MIA procedure was performed as described previously.¹² Briefly, microsphere mixtures were successively incubated and protected from the light on an orbital shaker with serum samples (1:400), biotinylated protein A and biotinylated protein G (4 µg/ml each) (Thermo Fisher Scientific) and streptavidin-R-phycoerythrin (4 µg/ml) (Life technologies). Measurements were performed using a Magpix instrument (Luminex). Relative fluorescence intensities (RFI) were calculated for each sample by dividing the MFI signal measured for the antigen-coated microsphere sets by the MFI signal obtained for the control microsphere set, to account for nonspecific binding of antibodies to beads. Specific seropositivity cutoff values for each antigen were set at three standard deviations above the mean RFI of the 29 canine and 30 feline serum samples sampled before 2019. Based on the pre-pandemic population, MIA specificity was set at 96.6% for N protein for dogs and cats, at 96.6% for RBD for cats and 100% for dogs and 100% for tri-S for cats and 96.6% for dogs.

Neutralisation activity measurement

To measure the neutralising activity in canine and feline sera, an MLV-based pseudoparticle carrying a GFP reporter pseudotyped with SARS-CoV-2 spike (SARS-CoV-2pp) was used. Each SARS-CoV-2-positive sample detected by MIA was processed according to neutralisation procedure as previously described.¹³ The level of infectivity was expressed as percentage of GFP positive cells and compared to cells infected with SARS-CoV-2pp incubated without serum. Pre-pandemic sera from France were used as negative controls, and anti-SARS-CoV-2 RBD antibody was used as positive control.

RESULTS

A sudden and atypical increased number of domestic cats and dogs with myocarditis was observed at the

Cardiology Department of TRVRC between December 2020 and February 2021. Indeed, the incidence of myocarditis cases over the preceding 12 months was 1.4% of all cardiology cases referred to TRVRC, while the incidence of myocarditis cases suddenly increased to 12.8% of all cases seen from mid-December 2020 through February 2021 (of which 8.5% were cats and 4.3% were dogs). This sudden surge of myocarditis cases appeared to mimic the curve and timeline of the COVID-19 human pandemic in the United Kingdom due to the B.1.1.7 variant, starting in mid-December 2020, peaking at the end of January 2021, before returning to the historical rate by mid-February 2021 (Figure 1).

Seven domestic pets (six cats and one dog) with a diagnosis of suspected myocarditis were selected for COVID testing due to their history of direct contact in their household with people with suspected or confirmed SARS-CoV-2 infection. None of these pets had a history of travel out of the United Kingdom. Four other pets (two cats and two dogs) were also retrospectively tested for SARS-CoV-2 antibodies during their recovery phase, 2–6 weeks after they developed signs of cardiac disease. All pets were neutered and aged between 1 and 12 years. None of the 11 study animals with myocarditis developed any influenza-like symptoms and they all clinically improved within a few days of intensive care, although one cat (LL) was presented again 1 week after discharge with a relapse of clinical signs, characterised by profound lethargy and uncontrolled ventricular tachycardia, prompting the owners to elect for euthanasia.

Diagnostic investigations revealed the presence of elevated cardiac troponin-I (median 6.8; range 0.68–61.1 ng/ml; normal reference range 0.0–0.2 ng/ml), accompanied with echocardiographic evidence of myocardial remodelling. The majority of cases (eight cats and one dog) also had evidence of pleural effusion and/or pulmonary oedema, often confirmed on thoracic radiographs. Seven animals (four cats and three dogs) displayed severe ventricular arrhythmias on electrocardiography (Figure 2).

In all cases, additional diagnostic tests did not reveal any other potential viral, bacterial or protozoal causes of myocarditis, although these tests could not be performed in every patient due to financial reasons.

All affected animals made a remarkable improvement with cage rest, oxygen therapy, acute diuresis and, in some cases, anti-arrhythmic therapy with sotalol and fish oil supplementation before being discharged on oral medications after a few days of intensive care.

A cardiac recheck was performed 2–4 weeks after discharge in four cats and three dogs and, at that time, they were all displaying no clinical signs, with some echocardiographic evidence of reversed cardiac remodelling (Figure 3) and normalisation of the previously observed ECG abnormalities. Furthermore, their cardiac troponin level had returned to normal or near-normal values in all cases.

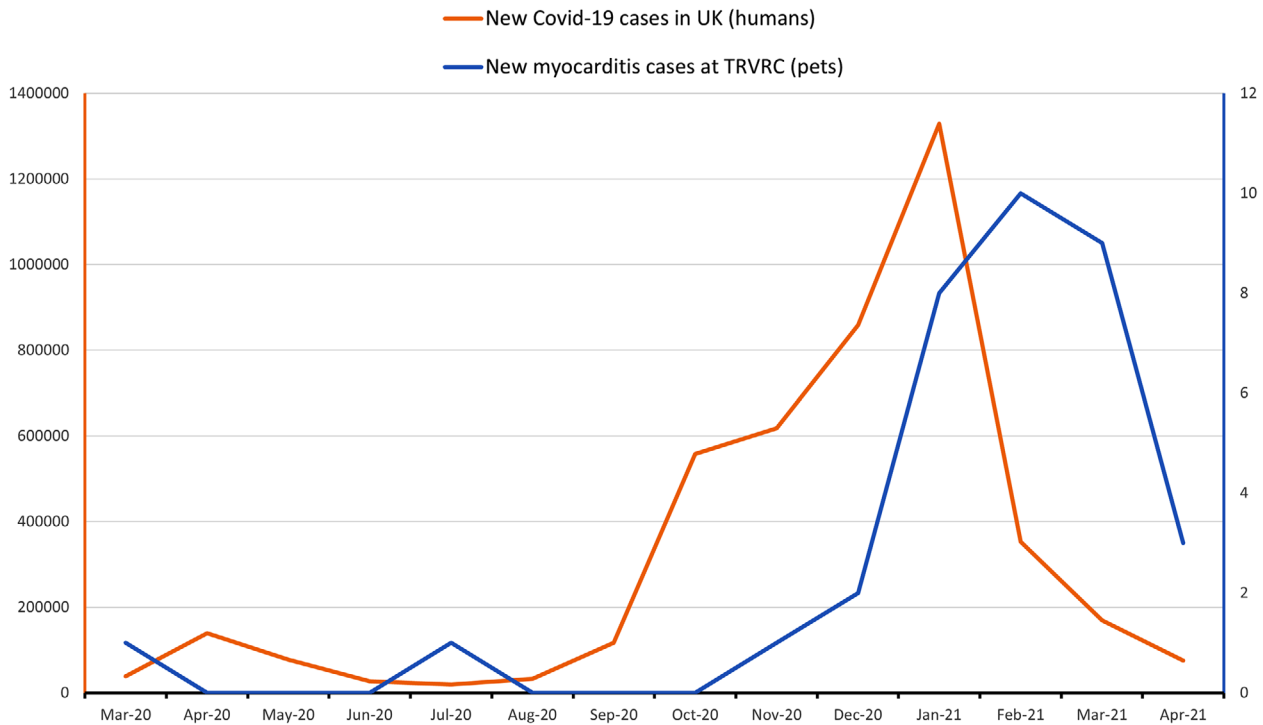


FIGURE 1 New cases of COVID-19 diagnosed in the United Kingdom between March 2020 and April 2021 (red line) compared to the number of cases of myocarditis diagnosed at The Ralph Veterinary Referral Centre in Marlow (UK) during the same period

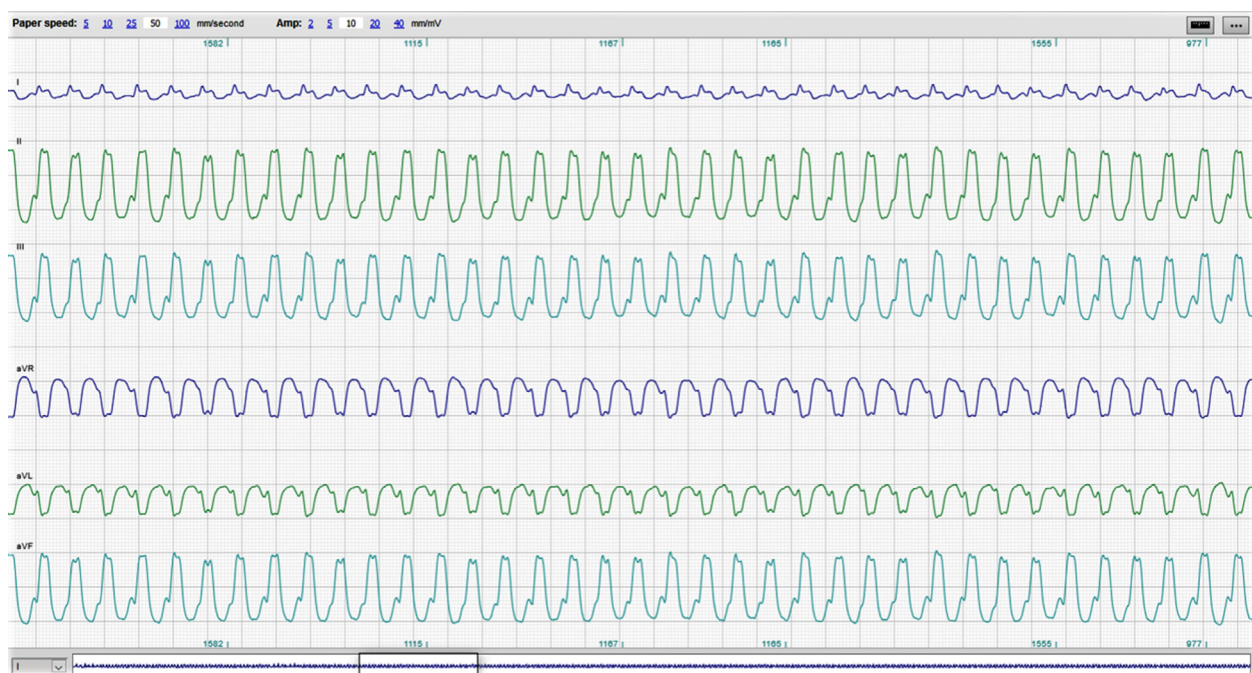


FIGURE 2 Electrocardiographic (ECG) trace recorded from one of the dogs presented with signs of acute myocarditis showing sustained monomorphic ventricular tachycardia at 320 bpm (sample obtained from a 5-min continuous six-lead ECG recording, 50 mm/s, 10 mm/mV)

All oro-nasopharyngeal swabs were found SARS-CoV-2 ddPCR negative. However, ddPCR-positive signals were obtained for the three regions from the rectal swabs from three of seven animals (two cats and one dog), indicating infection with the UK B.1.1.7 variant. Sequencing of the fragment amplified from the HY cat confirmed UK B.1.1.7 infection (Figure 4). The RNA concentration ranged from 12 to 33 copies/ μ l of specimen, indicating low viral load (Table 1). In addition,

one animal sampled during the acute phase of the disease, which tested ddPCR negative, as well as two of four animals sampled during the recovery period, were found to have SARS-CoV-2 antibodies. Therefore, in total, six of our 11 investigated animals were shown SARS-CoV-2 positive, either by ddPCR or by serology. More interestingly, considering only the five animals from which owners or handlers were laboratory confirmed COVID-19 positive, four were shown

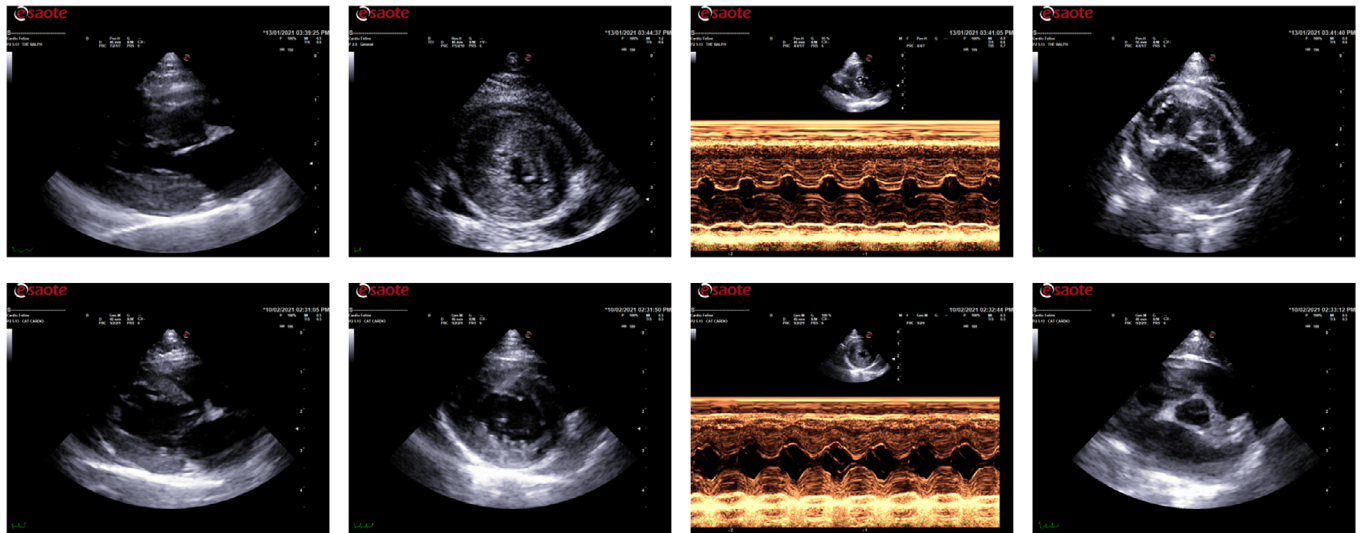


FIGURE 3 Echocardiographic images of a 1-year-old female Siberian cat presented with acute signs of congestive heart failure. The top row shows images obtained at the initial presentation and the bottom row reports images obtained at a 4-week cardiac recheck. All these images were obtained from a right parasternal view. From left to right: long axis four-chamber view; short axis view at the level of the papillary muscles; M-mode study of the left ventricle; short axis at the level of the heart base. The images show a substantial reversed remodelling with resolution of the originally observed myocardial concentric hypertrophy and severe left atrial dilation

```

                21705
Wuhan-Hu-1 ... tacattcaactcaggacttggtcttacctttcttttccaatggttacttgggttccatgcta
Alpha       ... tacattcaactcaggacttggtcttacctttcttttccaatggttacttgggttccatgcta
HY         ... tacattcaactcaggacttggtcttacctttcttttccaatggttacttgggttccatgcta

                21787                                21822
Wuhan-Hu-1 ... tactaagaggtttgataaccctgtcctaccatttaa
Alpha       ... tactaagaggtttgataaccctgtcctaccatttaa
HY         ... tactaagaggtttgataaccctgtcctaccatttaa

.....

                22990                                23071
Wuhan-Hu-1 ... tagcacaccttgtaatggtggtgaaggttttaattggtactttcctttacaatcatatggtttccaaccctaatgggtgtt
Alpha       ... tagcacaccttgtaatggtggtgaaggttttaattggtactttcctttacaatcatatggtttccaaccctaatgggtgtt
HY         ... tagcacaccttgtaatggtggtgaaggttttaattggtactttcctttacaatcatatggtttccaaccctaatgggtgtt

                23072                                23133
Wuhan-Hu-1 ... ggttaccaaccatacagagtagtagtactttcttttgaacttctacatgcaccagcaactgt
Alpha       ... ggttaccaaccatacagagtagtagtactttcttttgaacttctacatgcaccagcaactgt
HY         ... ggttaccaaccatacagagtagtagtactttcttttgaacttctacatgcaccagcaactgt
    
```

FIGURE 4 Sequence of the amplified fragment obtained from one cat (HY) with PCR-positive test from the rectal swab

SARS-CoV-2 positive (Table 1). In this context, it may be worth mentioning that the number of infected owners may have been higher than estimated, as approximately one third of SARS-CoV-2-infected people are completely asymptomatic and, in such cases, do not undergo testing. Moreover, not all pet owners were prepared to disclose information about their health status, while others who experienced COVID-related symptoms were rather vague about the precise onset of their health problems.

DISCUSSION

To our knowledge, this is the first report of infection of both cats and dogs by the UK variant B.1.1.7 of

SARS-CoV-2,¹⁵ although additional cases have subsequently been reported in the United States.¹⁶ Given the enhanced infectivity and transmissibility of B.1.1.7 variant for humans, the discovery of B.1.1.7-infected cats and dogs highlights the potential risk that companion animals can become infected by SARS-CoV-2 more commonly than previously reported. However, we did not observe any finding to suggest a pet-to-pet or pet-to-human transmission by the B.1.1.7 variant. Nevertheless, it may be possible that the N501Y mutation and the Δ69-70 deletion may render the virus more infectious for these animals.

The other remarkable observation is that the infected dogs and cats in this study had cardiac manifestations compatible with a diagnosis of suspected myocarditis. This could be a potential coincidental

event and we should acknowledge the fact that we based our observations only on a population of pets referred to our cardiology service because of critical signs of heart disease. Nevertheless, the stark acute increase in the number of cases with a particular cardiovascular disease manifestation (i.e., number of cases of suspected myocarditis compared to other cardiac pathologies, expressed as a percentage of all cases referred to the cardiology service), and the observation that the incidence of this rise mimicked the curve and timeline of the COVID-19 human pandemic in the United Kingdom due to the B.1.1.7 variant (Figure 1), is rather compelling, even if not conclusive. With the exception of only one published case report from Spain about a cat that developed cardiorespiratory failure resulting in severe respiratory distress, both natural and experimental SARS-CoV-2 infections of cats and dogs have so far been reported to be either asymptomatic or display respiratory disease.^{7,8,14} Although the B.1.1.7 infection in humans seems to be associated with higher COVID-19 mortality or clinical severity, the apparent potential association between B.1.1.7 infection and myocarditis in domestic pets should be somewhat acknowledged and addressed.¹⁷ In this context, it is important to highlight the fact that myocarditis associated with multisystem inflammatory syndrome is also a well-recognised complication of COVID-19 in people (both adults and children, including some of the pet owners in this study), probably from exaggerated immune response of the host.^{18,19}

Finally, the identification of PCR-positive signals from the rectal swabs from three pets represents another novelty and suggests that a subset of animals may continue to have positive SARS-CoV-2 rectal swab after a negative result of nasopharyngeal test, as previously reported in human patients.²⁰ This highlights the potential of gastro-intestinal shedding of the virus even in asymptomatic individuals.

Some limitations of this observational study need to be acknowledged. First, the diagnosis of myocarditis could not be confirmed on endomyocardial biopsy due to the intrinsic risk associated with this invasive procedure and the unstable clinical condition of these pets. However, the same diagnostic ambiguity is also well reported in human cardiology, where a high suspicion of myocarditis arises in patients with acute onset of cardiac symptoms or ECG modifications, elevated cardiac troponin and echocardiographic abnormalities, like in the small cohort of cats and dogs in this study.²¹ Another important limitation is the incapacity to provide a definitive demonstration that myocarditis was directly or indirectly associated with SARS-CoV-2 infection, especially for the absence of an appropriate control group. However, even in this case, there are important analogies with human medicine where, although cardiac inflammation has been well documented in patients with COVID-19, at the moment there is no evidence of SARS-CoV-2 in human cardiomyocytes. Therefore, the possibility of a direct myocardial infection from the virus remains to be demonstrated. Interestingly, there is evidence

that most human patients with clinically suspected myocarditis secondary to COVID-19 have a favourable in-hospital outcome and are discharged, as observed in our cats and dogs.^{18,19}

In summary, our findings demonstrate for the first time the ability for companion animals to be infected by the B.1.1.7 variant of SARS-CoV-2 and raise questions regarding its potential pathogenicity in these animals. Therefore, we believe that there is a need for further studies on animal infections by highly transmissible variants, such as UK B.1.1.7, South African B.1.351 and Brazilian P.1 variants, as part of the global response to the ongoing multispecies COVID-19 pandemic.

ACKNOWLEDGEMENTS

We are grateful to the pet owners for giving us their permission to sample their pets. We also thank Dr. Laurent Locquet and Dr. Altin Cala for contributing to the clinical management of these patients and Mrs. Jo Farminer and Mr. Liam Hodsdon for their laboratory assistance at TRVRC. Thanks also to Franz Durandet (IAGE - Ingénierie et Analyse en Génétique Environnementale, Grabels, France), Alix de Mont-Marin (Innovative Diagnostics, France) and Afif M. Abdel Nour (Qiagen, France) for their help in molecular biology. We also thank François Loïc Cosset, Solène Denolly, Bertrand Boson from CIRI (Centre International de Recherche en Infectiologie), Team EVIR, Univ Lyon, Université Claude Bernard Lyon 1, Inserm, U111, UMR5308, ENS Lyon, for the development of the seroneutralisation technique. Finally, we thank Dr. Thierry Buronfosse for the kind gift of pre-pandemic sera.

CONFLICT OF INTEREST

The authors declare that there is no conflict of interest (financial or personal).

ETHICS STATEMENT

Ethical approval was not sought or required since all diagnostic tests and treatments undertaken were done so as part of standard clinical investigations and patient care under the Veterinary Surgeon's Act.


AUTHOR CONTRIBUTIONS

Luca Ferasin and Heidi Ferasin: Case selection, clinical management, sample collection, writing and reviewing manuscript. Eric Leroy: Laboratory analysis, critical review, writing and reviewing manuscript. Remaining authors: Laboratory analysis.

DATA AVAILABILITY STATEMENT

The data that support the findings of this study are available on request from the corresponding author. The data are not publicly available due to privacy or ethical restrictions.

ORCID

Luca Ferasin  <https://orcid.org/0000-0002-6898-7900>

REFERENCES

1. Rambaut A, Holmes EC, O'toole A, Hill V, Mccrone JT, Ruis C, et al. A dynamic nomenclature proposal for SARS-CoV-2 lineages to assist genomic epidemiology. *Nat Microbiol.* 2020;5:1403–7.
2. Van Eijk LE, Binkhorst M, Bourgonje AR, Offringa AK, Mulder DJ, Bos EM, et al. COVID-19: immunopathology, pathophysiological mechanisms, and treatment options. *J Pathol.* 2021;254(4):307–31.
3. Leung K, Shum MH, Leung GM, Lam TT, Wu JT. Early transmissibility assessment of the N501Y mutant strains of SARS-CoV-2 in the United Kingdom, October to November 2020. *Euro Surveill.* 2021;26:2002106.
4. Sawalha K, Abozenah M, Kadado AJ, Battisha A, Al-Akchar M, Salerno C, et al. Systematic review of COVID-19 related myocarditis: insights on management and outcome. *Cardiovasc Revasc Med.* 2021;23:107–13.
5. Barrs VR, Peiris M, Tam KWS, Law PYT, Brackman CJ, To EMW, et al. SARS-CoV-2 in quarantined domestic cats from COVID-19 households or close contacts, Hong Kong, China. *Emerg Infect Dis.* 2020;26:3071–4.
6. Sit THC, Brackman CJ, Ip SM, Tam KWS, Law PYT, To EMW, et al. Infection of dogs with SARS-CoV-2. *Nature.* 2020;586:776–8.
7. Hosie MJ, Epifano I, Herder V, Orton RJ, Stevenson A, Johnson N, et al. Respiratory disease in cats associated with human-to-cat transmission of SARS-CoV-2 in the UK. *bioRxiv.* 2020. <https://doi.org/10.1101/2020.09.23.309948>
8. Hosie MJ, Epifano I, Herder V, Orton RJ, Stevenson A, Johnson N, et al. Detection of SARS-CoV-2 in respiratory samples from cats in the UK associated with human-to-cat transmission. *Vet Rec.* 2021;188:e247.
9. Caforio AL, Pankuweit S, Arbustini E, Basso C, Gimeno-Blanes J, Felix SB, et al. Current state of knowledge on aetiology, diagnosis, management, and therapy of myocarditis: a position statement of the European Society of Cardiology Working Group on Myocardial and Pericardial Diseases. *Eur Heart J.* 2013;34:2636–48.
10. Falzone L, Musso N, Gattuso G, Bongiorno D, Palermo CI, Scalia G, et al. Sensitivity assessment of droplet digital PCR for SARS-CoV-2 detection. *Int J Mol Med.* 2020;46:957–64.
11. LI H. Minimap2: pairwise alignment for nucleotide sequences. *Bioinformatics.* 2018;34:3094–100.
12. Fritz M, Rosolen B, Krafft E, Becquart P, Elguero E, Vratskikh O, et al. High prevalence of SARS-CoV-2 antibodies in pets from COVID-19+ households. *One Health.* 2021;11:100192.
13. Legros V, Denolly S, Vogrig M, Boson B, Siret E, Rigail J, et al. A longitudinal study of SARS-CoV-2-infected patients reveals a high correlation between neutralizing antibodies and COVID-19 severity. *Cell Mol Immunol.* 2021;18:318–27.
14. Segales J, Puig M, Rodon J, Avila-Nieto C, Carrillo J, Cantero G, et al. Detection of SARS-CoV-2 in a cat owned by a COVID-19-affected patient in Spain. *Proc Natl Acad Sci U S A.* 2020;117:24790–3.
15. Ferasin L, Fritz M, Ferasin H, Becquart P, Legros V, Leroy EM. Myocarditis in naturally infected pets with the UK variant of COVID-19. *bioRxiv.* 2021. <https://doi.org/10.1101/2021.03.18.435945>
16. Hamer SA, Ghai RR, Zecca IB, Auckland LD, Roundy CM, Davila E, et al. SARS-CoV-2 B.1.1.7 variant of concern detected in a pet dog and cat after exposure to a person with COVID-19, USA. *Transbound Emerg Dis.* 2021. <https://doi.org/10.1111/tbed.14122>
17. Challen R, Brooks-Pollock E, Read JM, Dyson L, Tsaneva-Atanasova K, Danon L. Risk of mortality in patients infected with SARS-CoV-2 variant of concern 202012/1: matched cohort study. *BMJ.* 2021;372:n579.
18. Morris SB, Schwartz NG, Patel P, Abbo L, Beauchamps L, Balan S, et al. Case series of multisystem inflammatory syndrome in adults associated with SARS-CoV-2 infection - United Kingdom and United States, March–August 2020. *MMWR Morb Mortal Wkly Rep.* 2020;69:1450–6.
19. Valverde I, Singh Y, Sanchez-De-Toledo J, Theocharis P, Chikermene A, Di Filippo S, et al. Acute cardiovascular manifestations in 286 children with multisystem inflammatory syndrome associated with COVID-19 infection in Europe. *Circulation.* 2021;143:21–32.
20. Kipkorir V, Cheruiyot I, Ngure B, Misiani M, Munguti J. Prolonged SARS-CoV-2 RNA detection in anal/rectal swabs and stool specimens in COVID-19 patients after negative conversion in nasopharyngeal RT-PCR test. *J Med Virol.* 2020;92:2328–31.
21. Mele D, Flamigni F, Rapezzi C, Ferrari R. Myocarditis in COVID-19 patients: current problems. *Intern Emerg Med.* 2021;16(5):1123–9. <https://doi.org/10.1007/s11739-021-02635-w>

How to cite this article: Ferasin L, Fritz M, Ferasin H, Becquart P, Corbet S, Gouilh M, et al. Infection with SARS-CoV-2 variant B.1.1.7 detected in a group of dogs and cats with suspected myocarditis. *Vet Rec.* 2021;e944. <https://doi.org/10.1002/vetr.944>