



## Evaluation of microcirculation by Sidestream Dark Field imaging: Impact of hemodynamic status on the occurrence of pressure artifacts -A pilot study

Mathieu Magnin, Élisabeth Foulon, T. Lurier, Bernard Allaouchiche, Jeanne-Marie Bonnet-Garin, Stéphane Junot

### ► To cite this version:

Mathieu Magnin, Élisabeth Foulon, T. Lurier, Bernard Allaouchiche, Jeanne-Marie Bonnet-Garin, et al.. Evaluation of microcirculation by Sidestream Dark Field imaging: Impact of hemodynamic status on the occurrence of pressure artifacts -A pilot study. *Microvascular Research*, 2020, 131, pp.104025. 10.1016/j.mvr.2020.104025 . hal-03240997

**HAL Id: hal-03240997**

**<https://vetagro-sup.hal.science/hal-03240997>**

Submitted on 28 May 2021

**HAL** is a multi-disciplinary open access archive for the deposit and dissemination of scientific research documents, whether they are published or not. The documents may come from teaching and research institutions in France or abroad, or from public or private research centers.

L'archive ouverte pluridisciplinaire **HAL**, est destinée au dépôt et à la diffusion de documents scientifiques de niveau recherche, publiés ou non, émanant des établissements d'enseignement et de recherche français ou étrangers, des laboratoires publics ou privés.

# **Evaluation of microcirculation by Sidestream Dark Field imaging: Impact of hemodynamic status on the occurrence of pressure artifacts – A pilot study**

Mathieu Magnin<sup>a,b</sup>, Élisabeth Foulon<sup>a,b</sup>, Thibaut Lurier<sup>c,d,e</sup>, Bernard Allaouchiche<sup>a,f</sup>, Jeanne Marie Bonnet Garin<sup>a,b</sup>, Stéphane Junot<sup>a,g\*</sup>

<sup>a</sup> Université de Lyon, UR APCSe Aggressions Pulmonaires et Circulatoires dans le Sepsis, VetAgro Sup, 1 avenue Bourgelat F-69280 Marcy l'Etoile, France

<sup>b</sup> Université de Lyon, Vetagro Sup, Unité de Physiologie, Pharmacodynamie et Thérapeutique, 1 avenue Bourgelat F-69280 Marcy l'Etoile, France

<sup>c</sup> Université Clermont Auvergne, INRAE, VetAgro Sup, UMR EPIA, Theix F-63122 Saint-Genès-Champanelle, France

<sup>d</sup> Université de Lyon, INRAE, VetAgro Sup, UMR EPIA, 1 avenue Bourgelat F-69280 Marcy F-69280 Marcy l'Etoile, France

<sup>e</sup> Université de Lyon, INRAE, VetAgro Sup, Usc 1233 UR RS2GP, 1 avenue Bourgelat F-69280 Marcy F-69280 Marcy l'Etoile, France

<sup>f</sup> Université de Lyon, Hospices Civils de Lyon, Centre Hospitalier Lyon Sud, Réanimation Médicale, 165 Chemin du Grand Revoyet F-69310 Pierre-Bénite, France

<sup>g</sup> Université de Lyon, VetAgro Sup, Anesthésiologie, 1 avenue Bourgelat F-69280 Marcy l'Etoile, France

\*Corresponding author: [stephane.junot@vetagro-sup.fr](mailto:stephane.junot@vetagro-sup.fr)

**Author emails:** [mathieu.magnin@vetagro-sup.fr](mailto:mathieu.magnin@vetagro-sup.fr), [elisa.foulon@vetagro-sup.fr](mailto:elisa.foulon@vetagro-sup.fr), [thibaut.lurier@vetagro-sup.fr](mailto:thibaut.lurier@vetagro-sup.fr), [bernard.allaouchiche@gmail.com](mailto:bernard.allaouchiche@gmail.com), [jeanne-marie.bonnet@vetagro-sup.fr](mailto:jeanne-marie.bonnet@vetagro-sup.fr), [stephane.junot@vetagro-sup.fr](mailto:stephane.junot@vetagro-sup.fr)

**Conflict of interest statement:** The authors declare that there are no conflicts of interest related to this article.

**Source of support:** This work was supported by VetAgro Sup - Veterinary Campus of Lyon, University of Lyon, France.

### **List of Abbreviations**

AICc: Corrected Akaike Criterion

BSA: Body surface area

CI: cardiac index

CO: Cardiac output

DAP: Diastolic arterial pressure

HI: Heterogeneity index

HVM: Handheld videomicroscope

IM: Intra-muscular

IV: Intra-venous

MAP: Mean arterial pressure

MFI: Microvascular flow index

MIQS: Microcirculation image quality score

OR: Odd ratio

PPV: Pulse pressure variation

SAP: Systolic arterial pressure

SDF: Sidestream dark field

## **Abstract**

**Objective:** The aims of the study were to evaluate the influence of hemodynamic status on pressure artefacts and the impact of pressure artefacts on microcirculatory flow.

**Methods:** Sublingual microcirculation was assessed using a Sidestream Dark Field handheld imaging device in 7 anesthetized piglets, submitted to pharmacologically-induced blood pressure variations. For each video, a pressure score of 0, 1, or 10 was assigned for the category "pressure artefacts" of the "microcirculation image quality score". Videos with a pressure score of 0 and 1 were considered as "passing videos". The videos with a score of 10 were considered as "failing videos". Multivariate logistic regression models and multivariate linear mixed models with individual random effects were used.

**Results:** As blood pressure decreased, the probability of obtaining a "failing video" increased ( $P = 0.0008$ ). Pressure scores of 10 influenced significantly the perfused De Backer score (small and all vessels), the proportion of perfused vessels (small and all vessels), the microvascular flow index and the heterogeneity index. Pressure scores of 1 influenced significantly the parameters above-mentioned, except the perfused De Backer score for all vessels.

**Conclusion:** The probability of obtaining pressure artefacts during recording of microcirculation videos was higher when the arterial pressure was low. The presence of acceptable pressure artifacts also influenced microcirculation analysis.

## **Keywords**

- Microcirculation
- Image acquisition
- Artefacts
- Sidestream Dark Field

## Introduction

Microcirculation is considered as a vital component of organ function. It is the component of circulation that regulates oxygen and nutrients supply to the cells [1]. Microvessels are defined as small vessels, with a diameter inferior to 20  $\mu\text{m}$ , that include arterioles, capillaries and venules [2]. Microcirculation alterations are associated with a poor outcome in various critical conditions [3,4]. In this regard, it is considered as a potential target for resuscitation maneuvers, particularly since the development of handheld videomicroscopes (HVM) and sidestream dark field (SDF) imaging that allow direct observation of microvessels at the patient's bedside. This second generation of HVM consists of a videomicroscope whose lens is surrounded by LEDs emitting green light ( $\lambda = 530 - 550 \text{ nm}$ ) captured by hemoglobin. The SDF microscope records short videos of a few seconds where dark vessels on a light field are observed [5]. With this technology, the sublingual area is most frequently used to monitor microcirculation [2,3].

In comparison with other technologies such as laser-based techniques, HVM has the advantage of allowing a direct visualization of microvessels and an estimation of functional parameters. Those include characterization of microvascular density and flow with dedicated scores. However, the calculation of these scores and their interpretation is highly dependent on the quality of the videos obtained. Thus, obtaining videos of good quality remains one the major limitation for videomicroscopy [6–9]. In order to better evaluate the recorded videos, Massey et al. have developed a quality score based on 6 criteria: illumination, duration, focus, content, stability and pressure [10]. In a study by Sallisalmi et al, only 30% of the videos were considered of excellent quality [6]. To a similar extent, Bemelmans et al. reported the impossibility of obtaining videos of good quality in around 20% of the patients included in their study [8]. Several factors may affect the quality of the videos : some are operator-

dependent, others are patient-dependent such as the physical status or the degree of sedation [7].

The main operator-dependent artifacts are associated with image instability and compression of structures by the camera [6]. Pressure artifacts occur when the operator applies an excessive pressure on the sublingual area, causing a misrepresentation of capillary flow. Pressure artifacts are characterized by abnormally slow and heterogenous flow, capillary flows that stop and restart or reverse [6,10,11]. In the study of Sallisalmi et al., pressure artifacts were the most frequent, occurring in 36% of the videos [6]. The second consensus on the assessment of sublingual microcirculation considered pressure artifacts as “the main technical challenge in performing HVM measurement” [2]. Hence, the analysis of poor-quality videos can be the source of bias and erroneous conclusions. Pressure artifacts were notably associated with a lower density of vessels, a lower percentage of vessels perfused and a lower flow rate [7].

Pressure artefacts are detected by observing the flow in the large venules, considered as sentinel vessels because of their greater sensitivity to pressure obstruction [2,10]. Even though it seems logical that the occurrence of pressure artifacts is correlated with low pressure inside the vessels, rendering them more compressible, this remains to be elucidated. To our knowledge, no study regarding a potential link between hemodynamic status and quality of videos has been published.

We performed a pilot study on an experimental pig model that aimed verify the following two hypotheses. The first hypothesis was that the occurrence of pressure artifacts is dependent on the pressure prevailing within the vessels and therefore on the patient's hemodynamic status. The second hypothesis was that the presence of pressure artefacts, even if considered as acceptable, can influence microcirculatory parameters.

## Materials and methods

This study used video clips recorded as part of another study that aimed to validate a new medical device (this study was conducted in accordance with the Guide for the Care and Use of Laboratory Animals and approved by the Ethics Committee of the institution – VetAgroSup - Campus Vétérinaire de Lyon - Ethical agreement: authorization number 1819).

- *Animals*

For the purpose of the original study, 7 female piglets were anesthetized and equipped for hemodynamic monitoring. The anesthetic protocol consisted in a premedication with a 1:1 mixture of tiletamine-zolazepam (ZOLETIL100, 100 mg.mL<sup>-1</sup>, Virbac, Carros, France) 3.0 mg.kg<sup>-1</sup> IM, associated with morphine (MORPHINE AGUETTANT, 10 mg.mL<sup>-1</sup>, Laboratoire Aguettant, Lyon, France) 0.2 mg.kg<sup>-1</sup> IM, followed by an induction with propofol (PROPOVET 10 mg.mL<sup>-1</sup>, Zoetis, Malakoff, France) 4.0 mg.kg<sup>-1</sup> IV, and a maintenance with sevoflurane (SEVOFLO, Zoetis, Malakoff, France) in 30% oxygen. Once anesthetized, the external right jugular vein was dissected for placement of a central venous catheter (Multicath 3 7.5Fr, Vygon, Ecoen, France). A 4F thermodilution catheter (PiCCO catheter 5 Fr, Getinge, Orléans, France) was inserted into the lower abdominal aorta through the right femoral artery and connected to a PiCCO system.

- *Hemodynamics monitoring*

The following hemodynamics parameters were continuously recorded: mean arterial pressure (MAP), systolic arterial pressure (SAP), diastolic arterial pressure (DAP), cardiac output (CO), pulse pressure variation (PPV). Cardiac index (CI) was calculated based on conventional equations ( $CI = CO/BSA$ ), with the body surface area (BSA) calculated as previously described [12].

- *Original study design*

After equipment and stabilization of the animals, a succession of hypotensive and hypertensive periods was performed. Hypotension was induced by inhalation of an increased concentration of sevoflurane. Hypertension was performed by administration of norepinephrine. The targeted MAP for hypotension ranged from 30 to 50 mmHg, whereas the targeted MAP for hypertension ranged from 90 to 110 mmHg.

- *Microcirculation imaging and procedures*

Six hundred and eighty-four video clips were considered in this study. They were taken from 7 pigs that were included in the original study (pig a: 108 videos, pig b: 87 videos, pig c: 79, pig d: 73 videos, pig e: 132 videos, pig f: 108 videos and pig g: 97 videos).

The video sequences were obtained from the sublingual area, using a SDF × 5 lens camera (Microscan, Microvision medical, Amsterdam, The Netherlands), with a standardized duration of 120 frames. A detailed description of the SDF technology is provided elsewhere [5].

Every video clip was recorded by the same trained investigator (MM). The training period lasted 2 weeks. During this period, the principal investigator was trained on the recording and analysis of microcirculation video recorded by SDF. The training took place at VetAgroSup and was carried out on anesthetized live animals (dogs, cats and pigs) and was provided by SJ, who has 6 years of experience in the use of SDF.

The videos were recorded with the videomicroscope carried by hand, and not fixed. The videomicroscope was connected to a computer using a dedicated software (AVA, Version 4.3C, Microscan, Microvision medical, Amsterdam, The Netherlands). A new sterile cap was placed on the videomicroscope for each pig. As soon as the MAP reached the target value, the videomicroscope was positioned in the oral cavity. Beforehand, the secretions of the mouth were wiped with swabs, as well as the optic's cap of the microscope. The recording procedures followed Trzeciak and colleagues [13] recommendations, in accordance with the consensus of



experts [2]: the videomicroscope was applied on contact with the sublingual mucosa until the microcirculation was observed. The camera was advanced into the sublingual area until the flow was partially or completely occluded. Then, it was retracted from the sublingual mucosal surface until contact with the tissue was lost. Just before contact was lost, the flow looked like with no pressure. Then, the probe was advanced again gently until a contact was regained and the microvessels came into view. Stability, focus and illumination were assessed by the AVA software and 3 to 10 videos were recorded, for at least three different sites. The procedure was in accordance with the consensus recommendations of experts [2].

All the videos were recorded at the floor of the mouth, near the lingual frenulum: during the introduction of the probe in the oral cavity, the tongue was slightly raised, allowing the visualization of the floor of the mouth and the lingual frenulum. The probe was placed gently in contact with the mucosa of the floor of the mouth, in the region around the lingual frenulum, at an angle of about 60 °.

- *Video clip analysis*

The video clips of the original study were analyzed blindly by two authors (MM and EF), trained to read microcirculation videos and to perform the “microcirculation image quality score (MIQS)” described by Massey et al [10]. The evaluators were blinded from one another and could not communicate regarding the videos and their scoring. For each video clip, they were not aware of the hemodynamic status of the animals at the time of its recording. Afterward, in case of disagreement, the two raters met to find a consensus. The overall acceptable quality videos were retained for further analysis.

For each video, a pressure score of 0, 1, or 10 was assigned for the category "pressure exerted by the videomicroscope" of the MIQS.

A pressure score of 0 was considered as “good” (“constant flow throughout the entire movie. No obvious signs of artificially sluggish or stopped flow. Good flow in the largest vessels”). A pressure score of 1 was considered as “acceptable” (“Signs of pressure, localized sluggish flow in a specific large vessel, but flow appears to be unimpeded based on good flow in most large vessels”). A pressure score of 10 was considered as “unacceptable” (“Obvious pressure artifacts associated with probe movement, and/or flow that starts and stops, reversal of flow. Poor or changing flow in larger venules”). Videos illustrating the level of pressure artifacts are available in additional files ([additional file](#)). The videos with a pressure score of 0 and 1 were grouped in the category of quality video “passing videos”. The videos with a score of 10 were considered as “failing videos”.

Microvascular flow index (MFI) and heterogeneity index (HI) were calculated by an author (MM). The MFI was evaluated as followed: the image was divided into 4 quadrants, a score of 0 to 3 is assigned to each (flow was characterized as absent (0), intermittent (1), sluggish (2), or normal (3)). The MFI corresponded to the average of these 4 scores. The HI was calculated from the quadrant scores according to the following equation:  $(\text{highest score} - \text{lowest score}) / \text{mean score}$  [2].

A validated automatic algorithm-software (AVA, Version 4.3C) performed others analysis. Small vessels were defined as vessels with diameter < 20  $\mu\text{m}$ . Density and perfusion related parameters were calculated as followed:

- o Density parameters:

- De Backer score (DBs) = number of crossings / total length of the 3X3 De Backer grid (in n/mm). This parameter was calculated for all vessels (DBs all) and for small vessels (DBs small).

- o Perfusion parameters:

- Perfused De Backer score (PDBs) = perfused number of crossings / total length of the 3X3 De Backer grid (in n/mm). This parameter was calculated for all vessels (PDBs all) and for small vessels (PDBs small).

- Proportion of Perfused Vessels (microPPV) = (Perfused De Backer score/De Backer score)\*100 (in %). This parameter was calculated for all vessels (microPPV all) and for small vessels (microPPV small).

- *Statistical analysis*

A Cohen's kappa coefficient ( $\kappa$ ) was calculated to determine the interrater reliability for passing or failing a video. To test the influence of hemodynamic parameters on the quality of the video (passing or failing), a multivariate logistic regression model was built with individual random effects. The complete model included as fixed effects CI, MAP, PPV and interaction terms of second and third order (formula 1). With the dredge function of the "MuMin" package, the corrected Akaike criterion (AICc) was calculated for all possible sub-models. The best of these sub-models was then selected as the model with the weakest AICc. Based on the selected model, the "emmeans" package was used to predict the probability of obtaining a "failing video" according to the hemodynamic status.

In order to test the impact of pressure artifacts on microcirculatory variables, a univariate analysis (formula 2) and a multivariate analysis (formula 3) were performed. For the univariate analysis, a linear mixed model was constructed for each microcirculatory parameter including the pressure score as a fixed effect and the individuals as random effects. For the multivariate analysis, the hemodynamic parameters (MAP, PPV and CI) were added as adjustment variables to verify whether the effect of the pressure artifacts was independent of the hemodynamic status. For MFI, logistic regressions were also performed including the

same variables as described above. The MFI was previously transformed into a dichotomous variable: a MFI below 2.6 was considered as abnormal whereas a MFI greater than 2.6 was considered as normal [2].

For the logistic models, the odds ratio (OR) of the fixed effects were calculated by performing the exponential of the estimate.

For each linear mixed model, homoscedasticity and random distribution of residuals were checked by plotting residuals against fitted value, and random distribution of individual random effect was checked by visualizing the distribution of individual random intercepts for each model. The correct fit of the logistic regressions was checked by performing a Pearson's residue analysis and a Hosmer-le-Cessie-Test if necessary.

Statistical analysis was performed using R 3.5.2 software (R Foundation for Statistical Computing, Vienna, Austria). The packages "ggplot2"[14], "Lme4"[15], "Lmertest"[16], "MuMIn"[17], "sjPlot"[18], "rms"[19] and "emmeans"[20] were used. A *P*-value lower than 0.05 was considered as significant.

*Formula 1: video quality (passing or failing) ~ CI \* MAP \* PPV + (1|individual)*

*Formula 2: Microcirculatory parameter ~ pressure score + (1|individual)*

*Formula 3: Microcirculatory parameter ~ pressure score + CI + MAP + PPV + (1|individual)*

## Results

- *Microcirculation image quality score*

An agreement between raters was observed in 89.3% of the cases (611/684) and a disagreement in 10.7% (74/684). Regarding the disagreements, 46% (34/74) represented strong disagreements (a video "0" or "1" was classified "10") and 54% (40/74) were regarded as minor disagreement (a video "0" was ranked "1"). Using the Cohen  $\kappa$  score to assess inter operator agreement for passing or failing a video with the blinded pressure score, a substantial agreement was observed ( $\kappa = 0.71$ ).

After consensus between operators, 456 (66.7%) video clips were considered as "good" (score of 0), 139 (20.3%) video clips were considered as "acceptable" (score of 1) and 89 (13%) video clips were considered as unacceptable (score of 10). Thus, 595 (87%) videos were regarded as appropriate and 89 (13%) were considered as poor quality.

- *Influence of hemodynamic status on the quality of videos*

Figure 1 illustrates the distribution of videos according to the pressure score (on x-axis) and the hemodynamic parameters (on the y-axis).

The best model for the quality of video was the model that included MAP only as an explanatory variable (model 1: video quality (passing or failing)  $\sim$  MAP + (1|individual)).

The results of the analysis are given in table 1: blood pressure significantly influenced the risk of obtaining a "failing video" ( $P = 0.0008$ ). Odd ratio was about 0.98; indicating that when blood pressure increases by 1mmHg, the probability of getting a video with unacceptable pressure artifacts is multiplied by 0.98. As blood pressure decreased, the probability of obtaining a "failing video" increased. The probability of obtaining a "failing video" as a function of MAP is presented in table 2 and illustrated in figure 2.

Table 1. Influence of hemodynamic status on the quality of videos

Fixed effect					Random effect	
Variable	Estimate (SE)	OR [IC95]	Z value	Pr(> z )	Variable	Variance (SD)
MAP	-0.024 (0.007)	0.98 [0.96 – 0.99]	-3.358	0.0008	individual	0.852 (0.923)

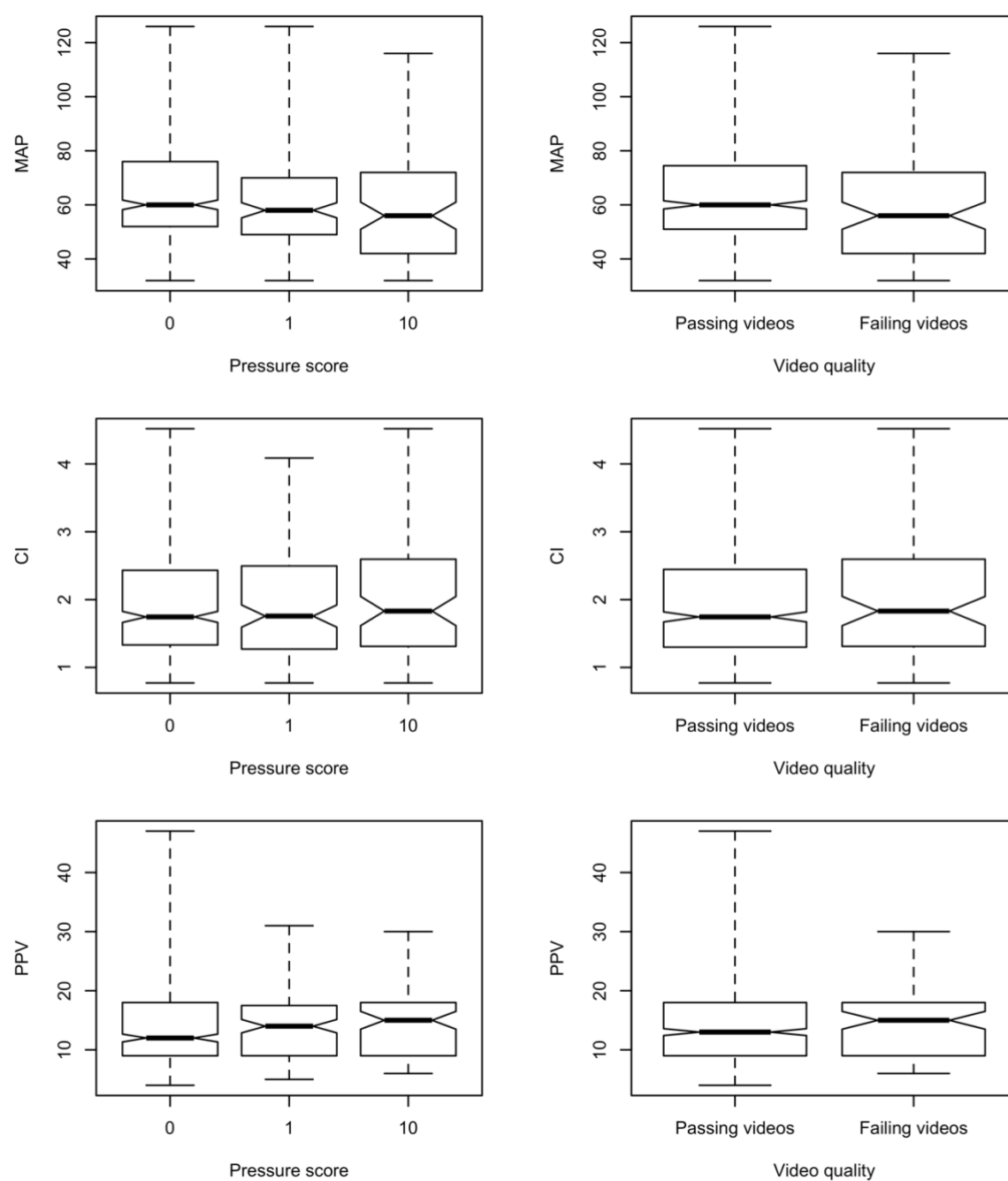
MAP: mean arterial pressure, SE: standard error, IC95: 95% confidence interval, SD: standard deviation, NA: not applicable.

Table 2. Probability of obtaining a failing video according to mean arterial pressure

MAP (mmHg)	Probability of obtaining a failing video (SE) (%)	95% confidence interval
30	20 (7)	10 - 37
50	14 (4)	7 - 25
70	9 (3)	4 - 17
90	6 (2)	2 - 12
110	4 (2)	1 - 9

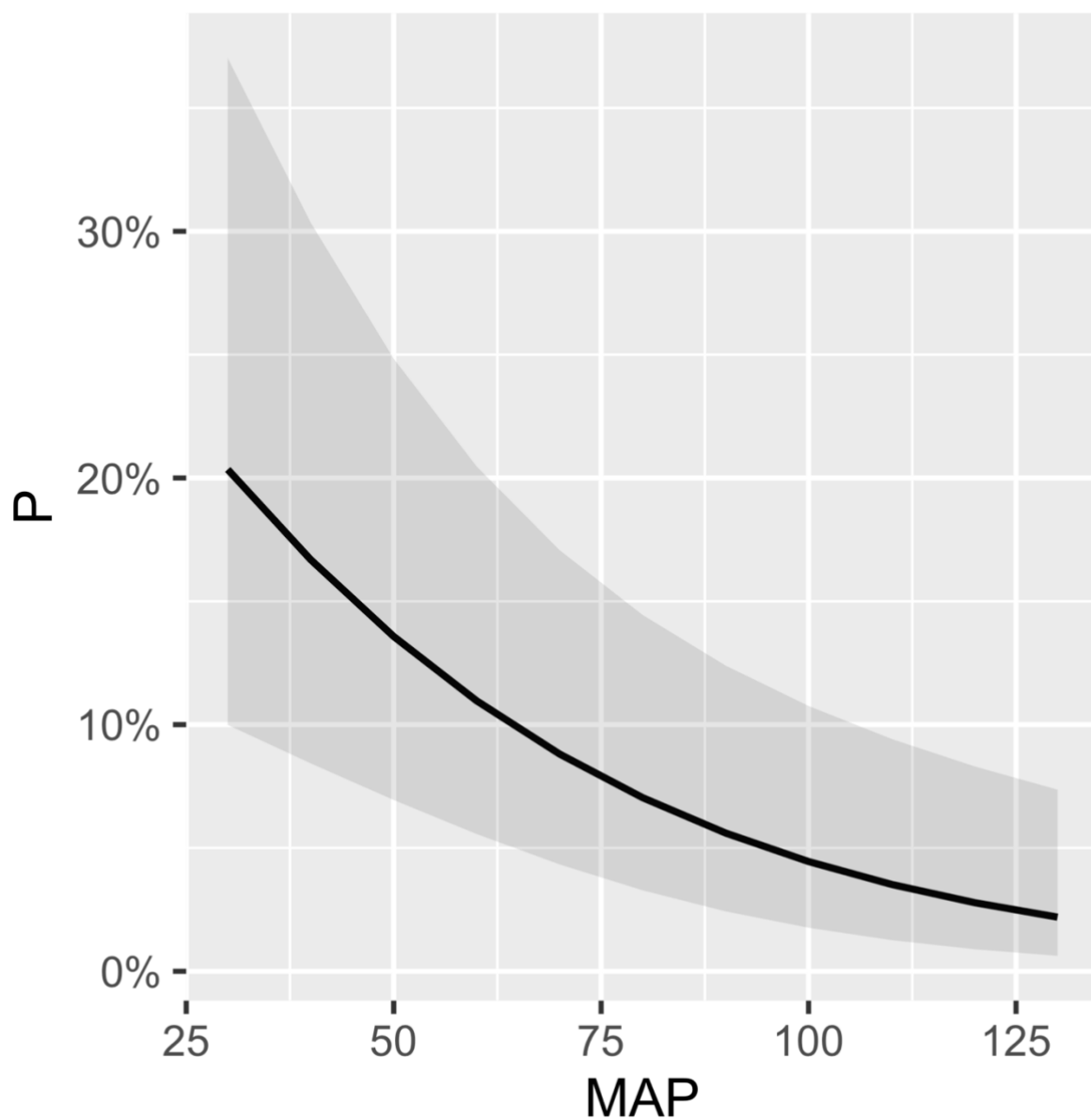
MAP: mean arterial pressure, SE: standard error

Figure 1. Distribution of videoclips according to hemodynamic status (y axis) and pressure score (x axis)



CI: cardiac index (L/min/m<sup>2</sup>), PPV: pulse pressure variation (%), MAP: mean arterial pressure (mmHg).

Figure 2. Probability of obtaining a failing video predicted according to mean arterial pressure



The black line corresponds to the probability of obtaining a "failing video" predicted by the model, the gray area around this line allows the representation of the 95% confidence interval.

MAP: mean arterial pressure (mmHg), P: probability of obtaining a failing video according to the model (%)



- *Influence of pressure score on microcirculatory parameters*

The results of univariate and multivariate analysis are described in table 3. Density (DBs, DBs small) was not influenced by the pressure score. PDBs for all vessels was significantly lower in videos with a pressure score of “10” compared with videos with a pressure score of “0”. PDBs small, microPPV, microPPV small and MFI were significantly lower in videos with a pressure score of “1” and in videos with a pressure score of “10”. HI was significantly higher in videos with a pressure score of “1” and “10”. The effect size was more important for videos with a pressure score of 10. Graphical presentations of microcirculatory parameters are illustrated in figure 3.

Table 3. Impact of pressure artifacts on microcirculatory parameters

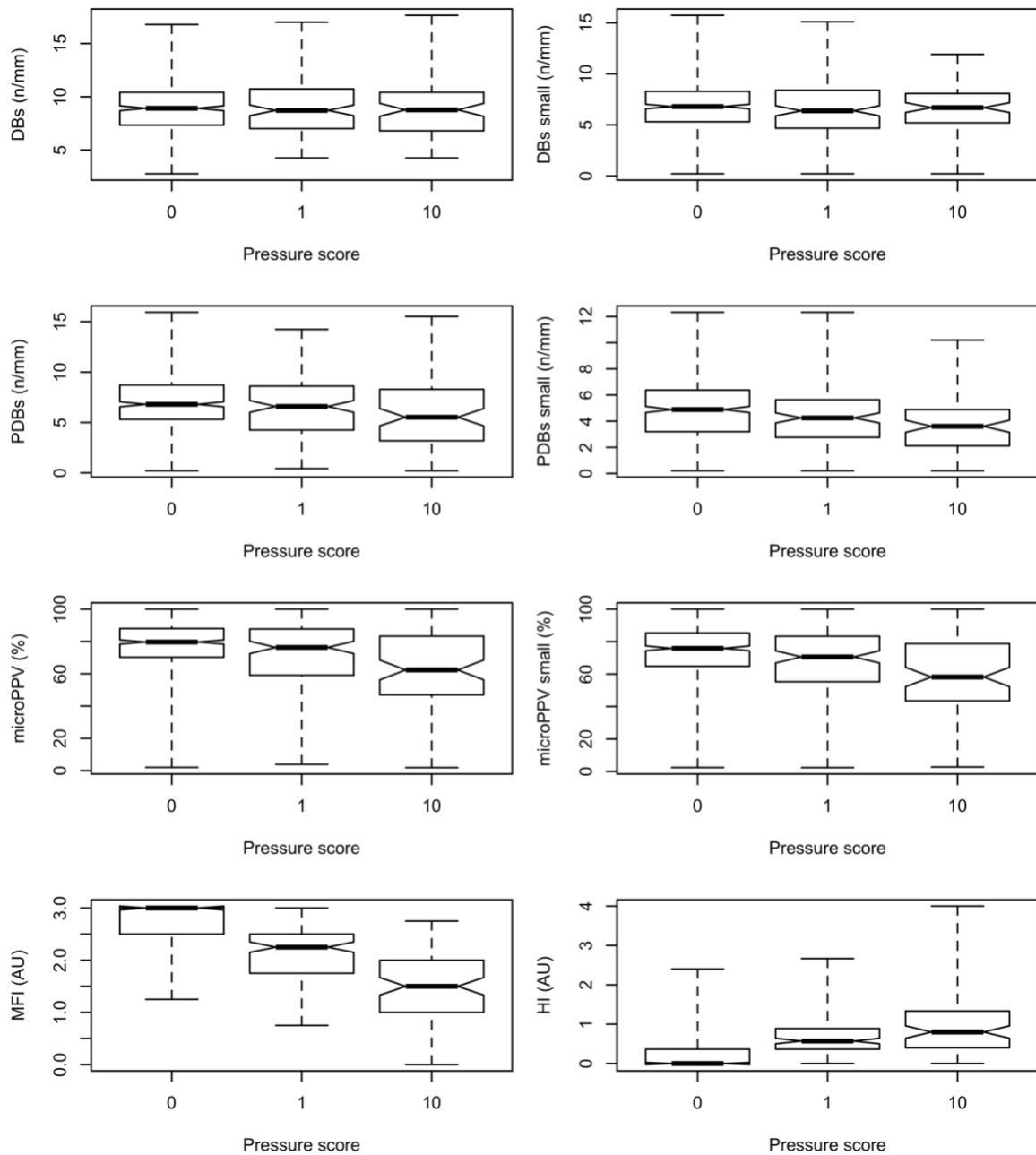
Dependent variable	Fixed effect	Univariate analysis		Multivariate analysis	
		Estimate	P-value	Estimate	P-value
DBs all	Pressure score “1”	-0.05 (-0.49 – 0.39)	0.83	-0.10 (-0.54 – 0.34)	0.65
	Pressure score “10”	-0.34 (-0.89 – 0.22)	0.24	-0.28 (-0.84 – 0.29)	0.34
	MAP			-0.001 (-0.014 – 0.011)	0.82
	CI			0.09 (-0.02 – 0.19)	0.13
	PPV			-0.03 (-0.06 – 0.01)	0.08
DBs small	Pressure score “1”	-0.38 (-0.84 – 0.10)	0.11	-0.42 (-0.89 – 0.05)	0.08
	Pressure score “10”	-0.37 (-0.94 – 0.23)	0.22	-0.37 (-0.96 – 0.24)	0.23
	MAP			$9.7 \cdot 10^{-4}$ (-0.01 – 0.01)	0.89
	CI			$-4.8 \cdot 10^{-2}$ (-0.16 – 0.07)	0.43
	PPV			$-5.54 \cdot 10^{-2}$ (-0.09 – 0.02)	0.002
PDBs all	Pressure score “1”	-0.26 (-0.76 – 0.25)	0.33	-0.29 (-0.81 – 0.22)	0.27

	Pressure score "10"	-1.01 (-1.65 - -0.38)	0.002	-1.05 (-1.72 - -0.39)	0.002
	MAP			-0.01 (-0.02 - 0.01)	0.26
	CI			0.06 (-0.07 - 0.19)	0.39
	PPV			-0.02 (-0.06 - 0.02)	0.26
PDBs small	Pressure score "1"	-0.55 (-0.98 - -0.12)	0.01	-0.59 (-1.02 - -0.16)	0.008
	Pressure score "10"	-1.0 (-1.53 - -0.47)	0.0002	-1.05 (-1.60 - -0.51)	0.0002
	MAP			-0.01 (-0.02 - 0.01)	0.29
	CI			-0.07 (-0.18 - 0.03)	0.16
	PPV			-0.05 (-0.08 - -0.02)	0.002
microPPV all	Pressure score "1"	-3.47 (-7.00 - 0.03)	0.05	-3.67 (-7.27 - -0.18)	0.04
	Pressure score "10"	-10.56 (-15.01 - -6.27)	<0.0001	-11.57 (-16.24 - -7.11)	<0.0001
	MAP			-0.10 (-0.20 - 0.00)	0.05
	CI			-0.02 (-0.91 - 0.85)	0.96
	PPV			-0.07 (-0.33 - 0.19)	0.57
microPPV small	Pressure score "1"	-3.57 (-7.33 - 0.08)	0.06	-3.75 (-7.58 - -0.04)	0.05
	Pressure score "10"	-12.08 (-16.81 - -7.52)	<0.0001	-13.19 (-18.15 - -8.47)	<0.0001
	MAP			-0.10 (-0.20 - 0.01)	0.07
	CI			-0.28 (-1.20 - 0.63)	0.55
	PPV			-0.11 (-0.38 - 0.17)	0.45
MFI	Pressure score "1"	-0.57 (-0.66 - -0.49)	<0.0001	-0.58 (-0.66 - -0.49)	<0.0001
	Pressure score "10"	-1.23 (-1.33 - -1.13)	<0.0001	-1.23 (-1.33 - -1.12)	<0.0001
	MAP			$2.10 \cdot 10^{-5}$ (-0.002 - 0.002)	0.98
	CI			$-4.58 \cdot 10^{-4}$ (-0.02 - 0.02)	0.97
	PPV			$-3.38 \cdot 10^{-4}$ (-0.01 - 0.01)	0.91
Binary MFI (normal or abnormal)	Pressure score "1"	OR=11.9 (7.3 - 19.8)	<0.0001	OR=11.8 (7.3 - 19.9)	<0.0001
	Pressure score "10"	OR=114.4 (34.7 - 706)	<0.0001	OR=111 (33.8 - 692.3)	<0.0001

	MAP			OR= 1 (0.9 – 1.1)	0.62
	CI			OR=1.1 (0.9 – 1.2)	0.46
	PPV			OR= 1 (0.9 – 1.1)	0.26
HI	Pressure score “1”	0.47 (0.38 – 0.56)	<0.0001	0.48 (0.38 – 0.57)	<0.0001
	Pressure score “10”	0.85 (0.74 – 0.97)	<0.0001	0.84 (0.72 – 0.96)	<0.0001
	MAP			5.54 $10^{-4}$ (-0.002 – 0.003)	0.67
	CI			-0.02 (-0.04 – 0.01)	0.17
	PPV			1.71 $10^{-3}$ (-0.01 – 0.01)	0.62

Values in parentheses correspond to 95% confidence intervals of model estimates or odd ratio. DBs: De Backer score, PDBs: Perfused De Backer score, microPPV: Proportion of Perfused Vessels, MFI: Microvascular Flow Index, HI: Heterogeneity Index, MAP: mean arterial pressure, CI: cardiac index, PPV: pulse pressure variation, OR: odd ratio

Figure 3. Microcirculatory parameters



DBs: De Backer score, PDBs: Perfused De Backer score, microPPV: Proportion of Perfused Vessels, MFI: Microvascular Flow Index, HI: Heterogeneity Index, n: number of crossing vessels, AU: Arbitrary Unit.

## Discussion

The current pilot study aimed to evaluate the influence of the hemodynamic status on the occurrence of pressure artifact during acquisition of SDF video clips and the impact of pressure artifacts on video analysis. The main results were an association between a low MAP and the occurrence of pressure artifact. In particular, the probability of obtaining a poor-quality video due to the presence of pressure artifacts increased when MAP decreased. Pressure artefacts significantly influenced the majority of microcirculatory parameters, even when these artefacts were considered acceptable. These results suggest that analyzing videos with moderate pressure artifacts could be a source of bias.

Microcirculation has been largely described, but its interest has gathered since the 1990s and the development of HVM [1,21]. Hence, this technology has contributed significantly to the understanding of the mechanisms underlying the evolution and prognosis of critical conditions. In particular, it has brought to light the occurrence of microcirculation disorders in the time-course of shock and sepsis [15,16]. Sidestream Dark Field imaging, the technology used in the present study, is the second generation of HVM. In comparison with the first generation, it has been associated with videos of better quality: capillary contrast and sharpness were shown to be significantly improved and venular granularity was more clearly observable compared with first generation [5]. As the other HVMs devices, it has the advantage over laser-based technologies of better characterizing the microcirculation by providing density and perfusion information. In addition, HVMs provide directly viewable anatomical information. However, its use is associated with some limitations, one of them being the acquisition of good quality videos. Indeed, SDF technology requires a certain skill to obtain clips of good quality, which can be analyzed and interpreted with limited risks of bias. Other limitations of SDF videomicroscopy are the restricted body area that can be investigated

and the clinical condition of the patients. Indeed, in critical care medicine, HVM is mainly used to evaluate microcirculation of the sublingual area for research purpose, and some severe conditions such as respiratory distress, prevent the placement of a microscope in the mouth [9]. When the recording is possible, the proportion of poor-quality videos obtained is not negligible and varies from 18 to 70% [6–8]. In a study performed on dialyzed patients with chronic kidney disease, good quality videos could not be obtained in 18% of the cases. In another cohort of 240 videos obtained in ICU, only 30% of the clips were considered as excellent quality. [6]. In another study carried out on critical patients, only 56% of the 2455 recorded videos were of sufficient quality to be analyzed. In this last study, the most striking result was that, for 20% of the patients, no video of appropriate quality could be recorded during their hospitalization [7]. Interestingly, the occurrence of large proportions of videos of poor quality appears mainly reported in ICU patients [6,7]. One possible explanation is that videos recorded on unstable patients must be obtained more quickly and in less favorable conditions (intubation, presence of many medical devices). However, other causes can explain the poor quality of a video, in particular the lack of experience of the manipulator or the absence of a standardized monitoring area. These results highlight the necessity to better understand the link between the physical status of the patient and the quality of videos obtained. In particular, it would be interesting to obtain videos in a more reliable manner in critical patients, who are the ones that could benefit the most from the analysis of microcirculation, as this may improve their outcome.

Based on the report of Sallisalmi et al.[6], Massey et al. [10] developed a scoring system to assess the quality of microcirculation video clips. This score includes 6 parameters that can be graded: illumination, duration, focus, content, stability and pressure artifacts. The current study focused on the "pressure artifact" described in the quality score. Pressure artifacts are

regarded as either absent, acceptable or unacceptable. This pressure artifact grading scale, which was hereby considered, is recommended by a task force consensus on the assessment of sublingual microcirculation in critically ill patients [2]. Within the quality score, the "pressure artifact" was associated a good repeatability, with a Cohen's Kappa of 0.82 [10]. In our study, a similar agreement between the two observers was found ( $\kappa = 0.71$ ). However, in the study performed by Sallisalmi et al [6], the definitions were less formalized and the repeatability of the pressure artifacts was significantly lower ( $\kappa = 0.50$ ).

As previously mentioned, pressure artifacts are, with lack of stability, the main reasons for obtaining poor quality videos [6,7]. The consensus on the analysis of sublingual microcirculation videos defined pressure artefacts as "the main technical challenge in performing HVM measurement"[2]. In the study by Sallisalmi et al, pressure artifacts were present in 36% of patients (26% of ventilated patients and 56% of non-ventilated patients). Regarding the learning curve of the operators performing the videos, the proportion of pressure artifacts remained elevated at the end of the training (28%) [6]. In the present study, 67% of the videos had no pressure artifacts, 20% presented acceptable artifacts and 13% unacceptable artifacts. These results are close to those observed in critical patients in the study by Damiani et al. [7].

The occurrence of pressure artifacts can be explained by technical difficulties. The videomicroscope is held manually by the operator who places it in contact with the sublingual mucosa, but without any control of the pressure exerted. As a weak force, equivalent to 1 / 6<sup>th</sup> of the weight of the microscope, is sufficient to generate compression of the microvessels, being unaware of the pressure exerted represents a limitation of the technology [24]. Thus, an appropriate training and experience are of major importance and can certainly help to

reduce these artifacts. It is therefore why the expert consensus recommends the implementation of such training [2].

Other factors, such as the patient physical condition and the hemodynamic status, may also promote pressure artifacts. In the current study, the hemodynamic characteristics, in particular MAP, were associated with the occurrence of pressure artefacts. Hence, these results tend to show that the more hypotensive the patient, the more difficult it is to avoid pressure artifacts. It is probably partly for this reason that the proportion of poor-quality videos is greater in studies performed on critical patients [6,7] than in other patients [8]. Other patient-related parameters have been identified. In the study of Damiani et al. [7], the cooperation of the patients seemed to be an important parameter for the acquisition of good videos: sedated patients, patients receiving mechanical ventilation or patients with a diminished state of consciousness were those for whom better videos were obtained. In other patients, even small movements of the tongue can cause artifacts. This issue was not encountered in our study, as the animals were anesthetized.

Thus, the operators need to be particularly cautious when obtaining videos from hypotensive patients, as pressure artefacts may occur. The relationship between blood pressure and pressure artefacts seems logical: if the pressure inside a vessel is high, it will offer more resistance to external compressive forces. Similarly, an association between hypovolemia and the presence of pressure artifacts could probably be found. However, compensatory mechanisms such as increasing vascular resistance may limit the compressibility of the vessels. Our study could not demonstrate an association between pulse pressure variation and the presence of pressure artifacts. Pulse pressure variation is sometimes considered as a surrogate of volemic status, however, it is in reality an indicator of the position on the Frank–Starling curve and fluid responsiveness. Thus, although dependent



on the blood volume, PPV is not strictly proportional to it, which can explain the absence of association between those parameters in our experimental setting. Furthermore, the pigs were not in severe hypovolemia during the experiment.

Performing an analysis on poor-quality videos can be a source of bias and incorrect conclusions. In the present study, all the microcirculatory parameters except the density ones (DBs, DBS small), were influenced by the pressure score. Interestingly, the density parameters were not affected by the pressure score, conversely to the perfusion and flow parameters. A possible explanation could be the pressure exerted by the microscope: it can limit the perfusion of the vessels by compressing them and thus slows down the flow, while increasing its heterogeneity since the compression is not homogeneously distributed. These results confirmed data from the literature: in the study by Damiani et al., poor-quality videos were associated with lower percentage of perfused vessels and a lower microvascular flow index [7]. However, the videos analyzed in the afore-mentioned study would have been considered as not acceptable according to the score of Massey et al. In addition, in the same study, the poor-quality score (measured by the MIQS) was associated with a reduction in the density parameters. This reduction was not observed in our study, but could be the consequences of other causes, such as illumination or focus artifacts that could limit the detection of vessels. As hypothesized, our study confirms that the presence of pressure artifacts, even if considered acceptable, can be a source of bias during the analysis. These results are interesting from a practical aspect, since only acceptable videos were considered, according to the score of Massey et al [10]. As these videos are usually retained for analysis, this highlights the possible occurrence of bias when assessing patients' microcirculation. These observations also emphasize the difficulty of distinguishing pressure artifacts and low MFI when analyzing videos. This confirms the importance of scoring the quality of videos before analyzing them.

Moreover, it seems advisable to record the possible presence of artifacts if they are suspected during the acquisition of videos, because it can be difficult to distinguish a low MFI from pressure artefacts afterwards.

We acknowledge some limitations for the present study. It was carried out in an experimental setting on pigs. Even if pigs and humans have physiological similarities, in particular regarding their cardiovascular system [12], these results must be confirmed in human patients.

An important limitation was related to the handling of the videomicroscope, which was not fixed to a support and without any pressure sensor. The pressure exerted by the investigator was therefore unknown and certainly different for each video. If the microscope was fixed to a support, this would have limited the impact of the manipulator and potentially allowed to better assess the impact of blood pressure on the pressure artifacts. Nevertheless, our registration conditions were similar to those performed in practice and followed the recommendations of Trzeciak et al. [13].

Hypotension was secondary to an overdose of sevoflurane and therefore was mainly due to vasoplegia [25]. Other causes of hypotension, such as hypovolemia, have not been investigated here, whereas it could have provided further insights in the influence of different hemodynamic determinants on SDF videomicroscopy.

Finally, the camera used in this study was a SDF microscope of second generation, whereas the pressure artefacts seem less frequent with the devices of latest generation [26,27]. The latest generation of HVM, using the incident dark field imaging technology (IDF), has been developed to reduce certain limitations of SDF imaging. These devices are much lighter, allow better tissue illumination and focus, with an enhanced resolution. One study compared the videos obtained with both technologies (IDF and SDF): the latest generation

was associated with better quality scores. In this study, no pressure artifact was observed with the IDF, which is most likely related to the light weight of the microscope (320g for SDF, 120g for IDF) [27]. However, the use of these devices does not prevent the creation of artefacts if the conditions of use are not correctly met. Stabilization devices have been described and may reduce pressure artefact if used cautiously [24], but, to our knowledge, they are not commercially available.

In conclusion, this experimental pilot study performed on a piglet model, highlights the higher probability of obtaining pressure artefacts during recordings of microcirculation SDF videos when the mean arterial pressure was low. These results demonstrate the relationship between hemodynamic status and quality of the videos. Even videos with acceptable pressure artifacts may be associated with decreased PDBs small, microPPV (small and all), MFI and an increased HI. As a consequence, special attention should be paid to avoid pressure artefacts during acquisition of microcirculation videos, especially in hypotensive patients. Microcirculatory parameters arising from videos with moderate pressure artefacts should be interpreted with caution. These results need to be confirmed in human patients.

## References

- [1] Granger HJ, Schelling ME, Lewis RE, Zawieja DC, Meininger CJ. Physiology and pathobiology of the microcirculation. *Am J Otolaryngol*. 1988;9(6):264–77. 10.1016/S0196-0709(88)80035-8.
- [2] Ince C, Boerma EC, Cecconi M, De Backer D, Shapiro NI, Duranteau J, et al. Second consensus on the assessment of sublingual microcirculation in critically ill patients: results from a task force of the European Society of Intensive Care Medicine. *Intensive Care Med*. 2018;44(3):281–99. 10.1007/s00134-018-5070-7.
- [3] Kara A, Akin S, Ince C. Monitoring microcirculation in critical illness. *Curr Opin Crit Care*. 2016;22(5):444. 10.1097/MCC.0000000000000335.
- [4] Donati A, Tibboel D, Ince C. Towards integrative physiological monitoring of the critically ill: from cardiovascular to microcirculatory and cellular function monitoring at the bedside. *Crit Care*. 2013;17(Suppl 1):S5. 10.1186/cc11503.
- [5] Goedhart PT, Khalilzada M, Bezemer R, Merza J, Ince C. Sidestream Dark Field (SDF)

imaging: a novel stroboscopic LED ring-based imaging modality for clinical assessment of the microcirculation. *Opt Express*. 2007;15(23):15101–14. 10.1364/OE.15.015101.

[6] Sallisalimi M, Oksala N, Pettilä V, Tenhunen J. Evaluation of sublingual microcirculatory blood flow in the critically ill. *Acta Anaesthesiol Scand*. 2012;56(3):298–306. 10.1111/j.1399-6576.2011.02569.x.

[7] Damiani E, Ince C, Scorcella C, Domizi R, Carsetti A, Mininno N, et al. Impact of microcirculatory video quality on the evaluation of sublingual microcirculation in critically ill patients. *J Clin Monit Comput*. 2017;31(5):981–8. 10.1007/s10877-016-9924-7.

[8] Bemelmans RHH, Boerma EC, Barendregt J, Ince C, Rommes JH, Spronk PE. Changes in the volume status of haemodialysis patients are reflected in sublingual microvascular perfusion. *Nephrol Dial Transplant*. 2009;24(11):3487–92. 10.1093/ndt/gfp267.

[9] González R, López J, Urbano J, Solana MJ, Fernández SN, Santiago MJ, et al. Evaluation of sublingual microcirculation in a paediatric intensive care unit: prospective observational study about its feasibility and utility. *BMC Pediatr*. 2017;17. 10.1186/s12887-017-0837-5.

[10] Massey MJ, LaRoche E, Najarro G, Karmacharla A, Arnold R, Trzeciak S, et al. The microcirculation image quality score: Development and preliminary evaluation of a proposed approach to grading quality of image acquisition for bedside videomicroscopy. *J Crit Care*. 2013;28(6):913–7. 10.1016/j.jcrc.2013.06.015.

[11] Massey MJ, Shapiro NI. A guide to human in vivo microcirculatory flow image analysis. *Crit Care*. 2016;20(1):35. 10.1186/s13054-016-1213-9.

[12] Swindle MM, Makin A, Herron AJ, Clubb FJ, Frazier KS. Swine as Models in Biomedical Research and Toxicology Testing. *Vet Pathol*. 2012;49(2):344–56. 10.1177/0300985811402846.

[13] Trzeciak S, Dellinger RP, Parrillo JE, Guglielmi M, Bajaj J, Abate NL, et al. Early microcirculatory perfusion derangements in patients with severe sepsis and septic shock: Relationship to hemodynamics, oxygen transport, and survival. *Ann Emerg Med*. 2007;49(1):88–98.e2. 10.1016/j.annemergmed.2006.08.021.

[14] Wickham H. *ggplot2: Elegant Graphics for Data Analysis* [homepage on the Internet]. New York: Springer-Verlag; 2009 [cited 2020 Jan 21]. 10.1007/978-0-387-98141-3. (Use R!).

[15] Bates D, Mächler M, Bolker B, Walker S. *Fitting Linear Mixed-Effects Models Using lme4*. *J Stat Softw*. 2015;67(1):1–48. 10.18637/jss.v067.i01.

[16] Kuznetsova A, Brockhoff PB, Christensen RHB. *lmerTest Package: Tests in Linear Mixed Effects Models*. *J Stat Softw*. 2017;82(1):1–26. 10.18637/jss.v082.i13.

[17] Burnham KP, Anderson DR. *Model Selection and Multimodel Inference: A Practical Information-Theoretic Approach* [homepage on the Internet]. 2nd ed. New York: Springer-Verlag; 2002 [cited 2020 Jan 21]. 10.1007/b97636.

[18] Daniel Lüdecke. *sjPlot - Data Visualization for Statistics in Social Science*. [homepage on the Internet]. Zenodo; 2018 [cited 2020 Jan 21]. 10.5281/zenodo.2400856.

[19] Jr FEH. *rms: Regression Modeling Strategies* [homepage on the Internet]. 2019 [cited 2020 Jan 21].

[20] Lenth R, Singmann H, Love J, Buerkner P, Herve M. *emmeans: Estimated Marginal Means, aka Least-Squares Means* [homepage on the Internet]. 2019 [cited 2020 Jan 21].

[21] Ocak I, Kara A, Ince C. Monitoring microcirculation. *Best Pract Res Clin Anaesthesiol*. 2016;30(4):407–18. 10.1016/j.bpa.2016.10.008.

[22] De Backer D, Orbegozo Cortes D, Donadello K, Vincent J-L. Pathophysiology of microcirculatory dysfunction and the pathogenesis of septic shock. *Virulence*. 2014;5(1):73–9. 10.4161/viru.26482.

- [23] De Backer D, Creteur J, Preiser J-C, Dubois M-J, Vincent J-L. Microvascular Blood Flow Is Altered in Patients with Sepsis. *Am J Respir Crit Care Med*. 2002;166(1):98–104. 10.1164/rccm.200109-016OC.
- [24] Balestra GM, Bezemer R, Boerma EC, Yong Z-Y, Sjauw KD, Engstrom AE, et al. Improvement of Sidestream Dark Field Imaging with an Image Acquisition Stabilizer. *BMC Med Imaging*. 2010;10:15. 10.1186/1471-2342-10-15.
- [25] De Hert S, Moerman A. Sevoflurane. *F1000Research*. 2015;4(F1000 Faculty Rev):626. 10.12688/f1000research.6288.1.
- [26] van Elteren HA, Ince C, Tibboel D, Reiss IKM, de Jonge RCJ. Cutaneous microcirculation in preterm neonates: comparison between sidestream dark field (SDF) and incident dark field (IDF) imaging. *J Clin Monit Comput*. 2015;29(5):543–8. 10.1007/s10877-015-9708-5.
- [27] Gilbert-Kawai E, Coppel J, Bountziouka V, Ince C, Martin D. A comparison of the quality of image acquisition between the incident dark field and sidestream dark field video-microscopes. *BMC Med Imaging*. 2016;16. 10.1186/s12880-015-0078-8.